Current trends in Cardiovascular Imaging and Improving Outcomes

Dr. Pallavi Bellamkonda MD MBA

Disclosure:
No Financial disclosures

Objectives

- Discuss latest advances in Cardiac Imaging modalities, and the effect on Cardiovascular outcomes
  - ECHO: Transthoracic & Transesophageal
  - CT : Calcium score, Coronary CTA, CT-FFR
  - Cardiac MRI

Advances in Echocardiogram:

1. Evaluation of Cardiac Function:
   a. Systolic &
   b. Diastolic

1. Valvular Heart disease

Cardiac Function: Systolic

- Cardiac function is a major determinant of Prognosis

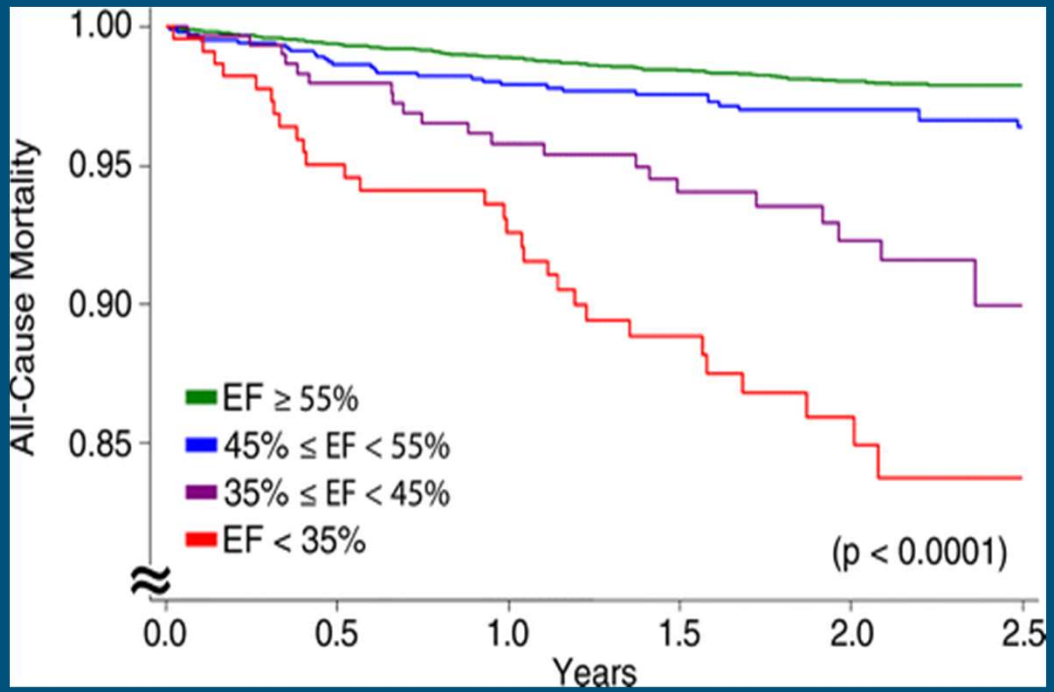

3D ECHOCARDIOGRAPHY

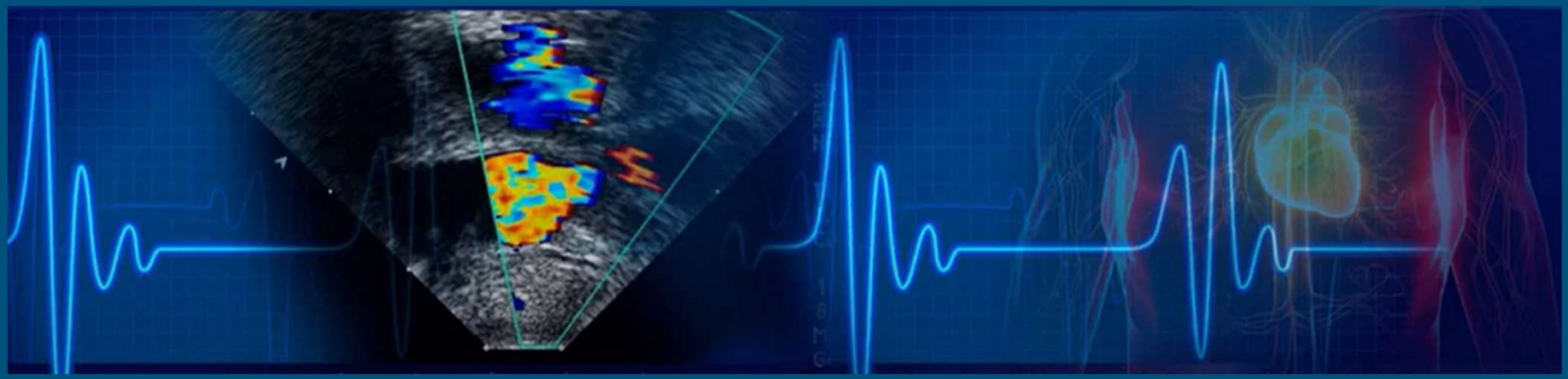

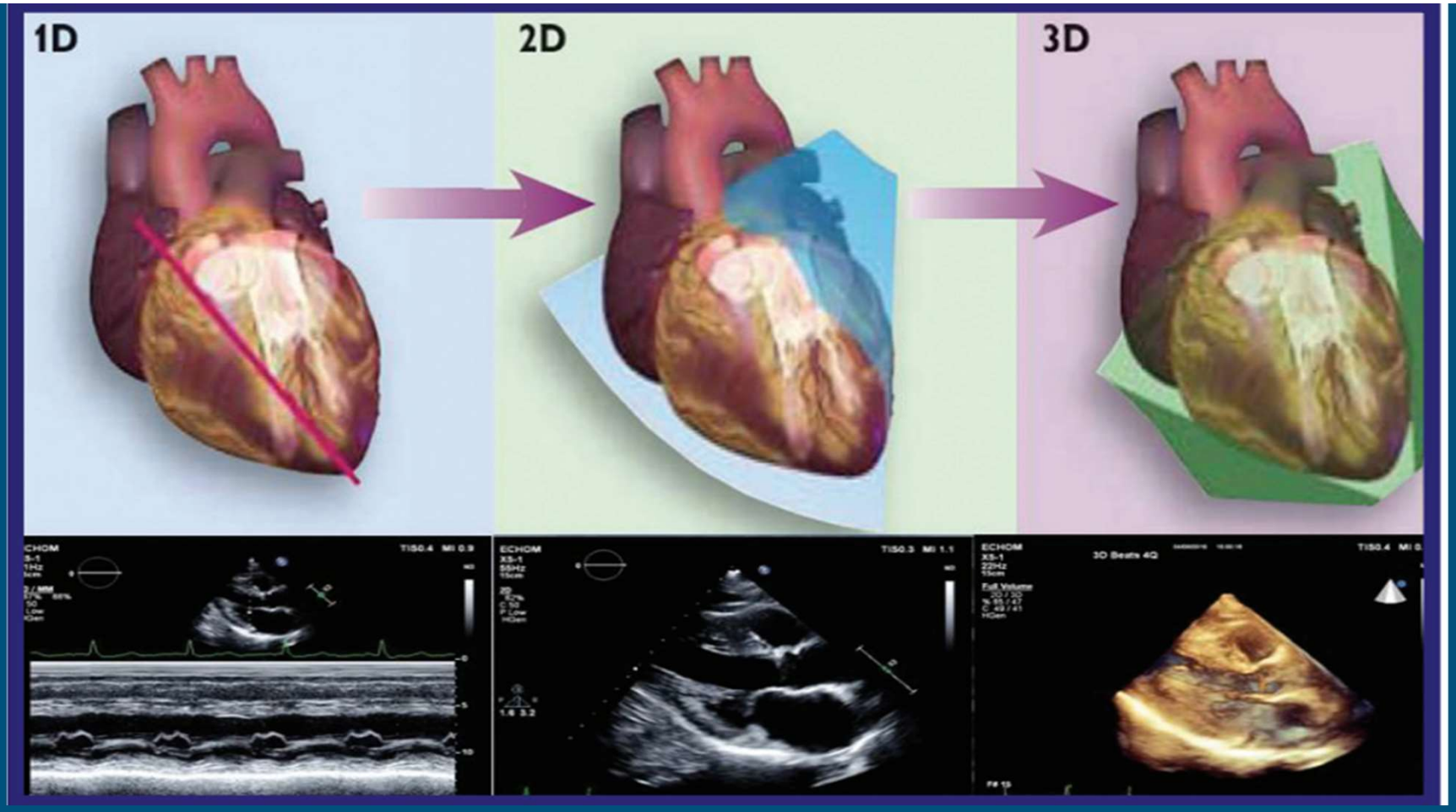

One-dimensional A-mode and M-mode techniques, - developed to 2D and 3D echocardiography

3D Echo

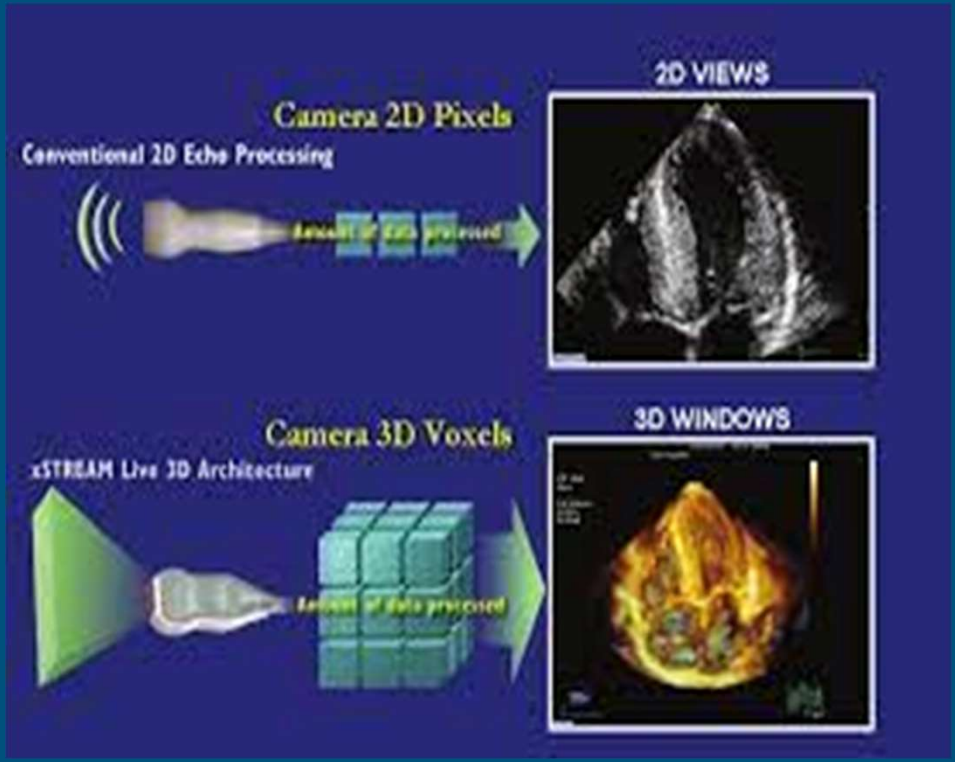
2D VIEWS
Camera 2D Pixels
Conventional 2D Echo Processing
Camera 3D Voxels
xSTREAM Live 3D Architecture
3D WINDOWS

3 D : Volumes and EF

- Live 3 D
- 1-4 beat acquisition
- Low frame rate

- Patient motion
- Patient breathing
- Arrhythmias

- Can cause artifact and lower image quality.

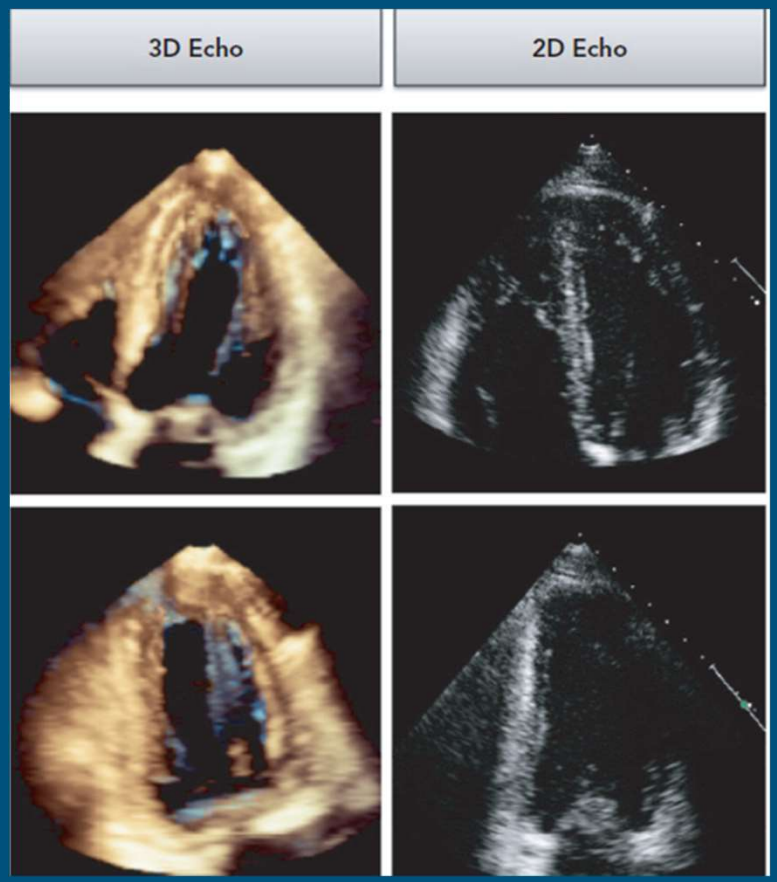

3D ECHO vs Cardiac MRI: EF comparison

	EDV (mL)	ESV (mL)	EF (%)
MRI	163.1 ± 55.0	86.2 ± 38.0	47.9 ± 6.7
3DE	144.4 ± 51.7	77.1 ± 35.7	47.7 ± 7.8
AD (%)	18.7 (12.2)	9.1 (11.1)	0.2 (0.4)

Data are means, standard deviations, and absolute difference (AD) of right ventricular volumes and ejection fraction measured by MRI and 3DE. EDV, end-diastolic volume; ESV, end-systolic volume; EF, ejection fraction.

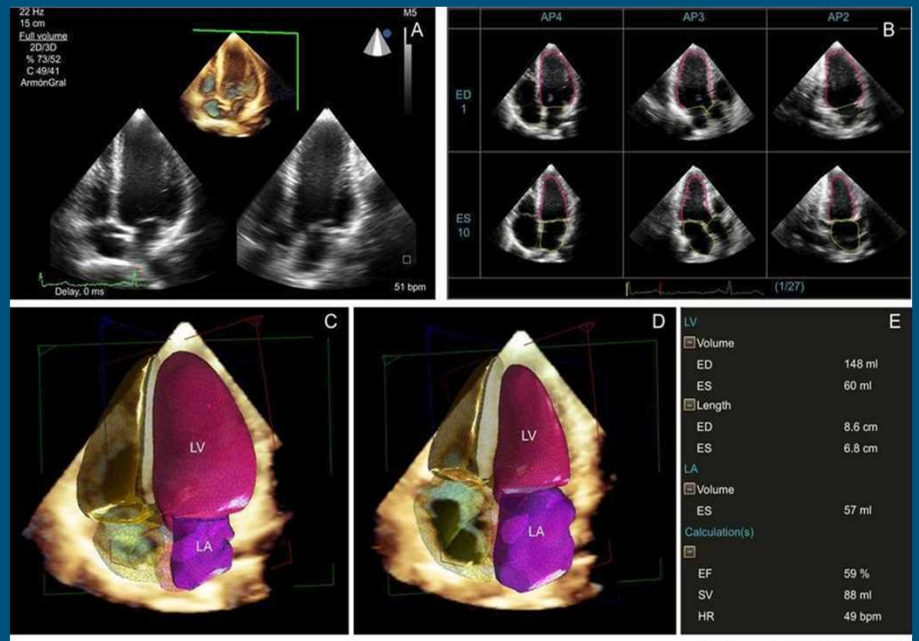

Rev Esp Cardiol. 2017;70:487–95

more... 3 D: Applications:

- Mitral valve
- Aortic valve
- Interatrial septum : PFO/ASD

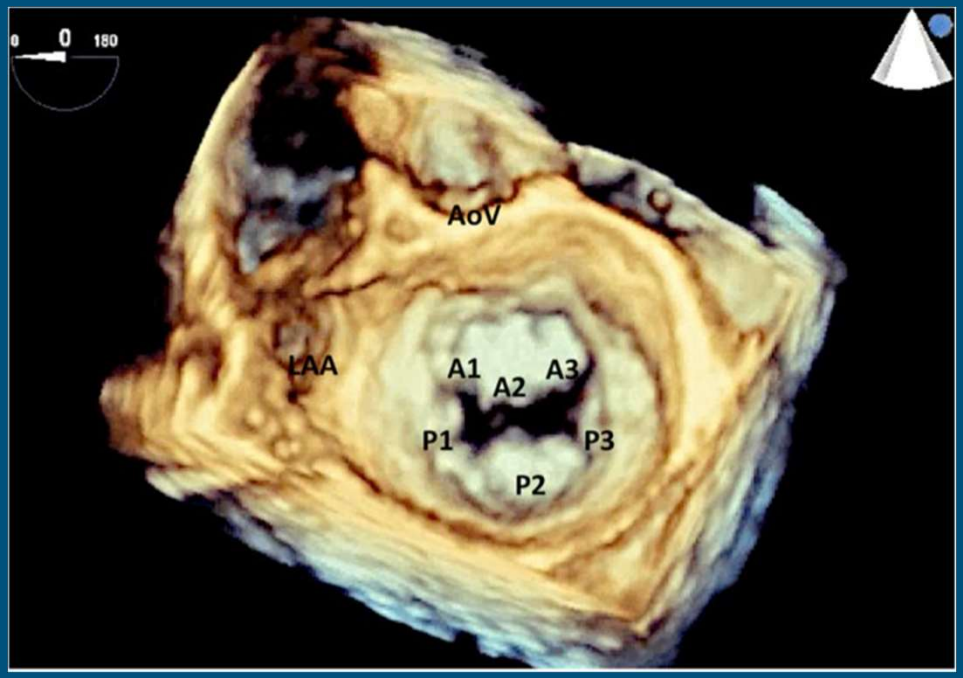

3 D: Valvular dysfunction

- Full volume/ 3 D- Zoom
- color filters can be used to eliminate low velocity dopplers that obsures the origin of the MR jet.
- Limitations:
  - Low temporal resolution
  - Stitch and drop out artifacts- that could simulate some pathologies.

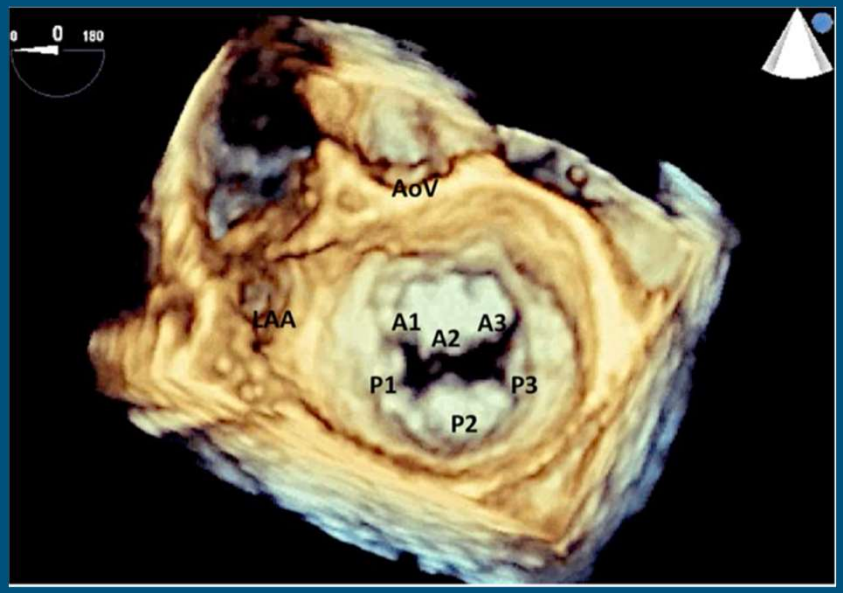

3D ECHO APPLICATIONS

- Disease Diagnosis: Assessment of anatomic and functional pathology
- Guide Interventions (percutaneous and Surgical)
- Assessing the intervention results
- Assessing LV and RV volumes and EF.

Diastolic Dysfunction

Diastolic Dysfunction: Prognosis

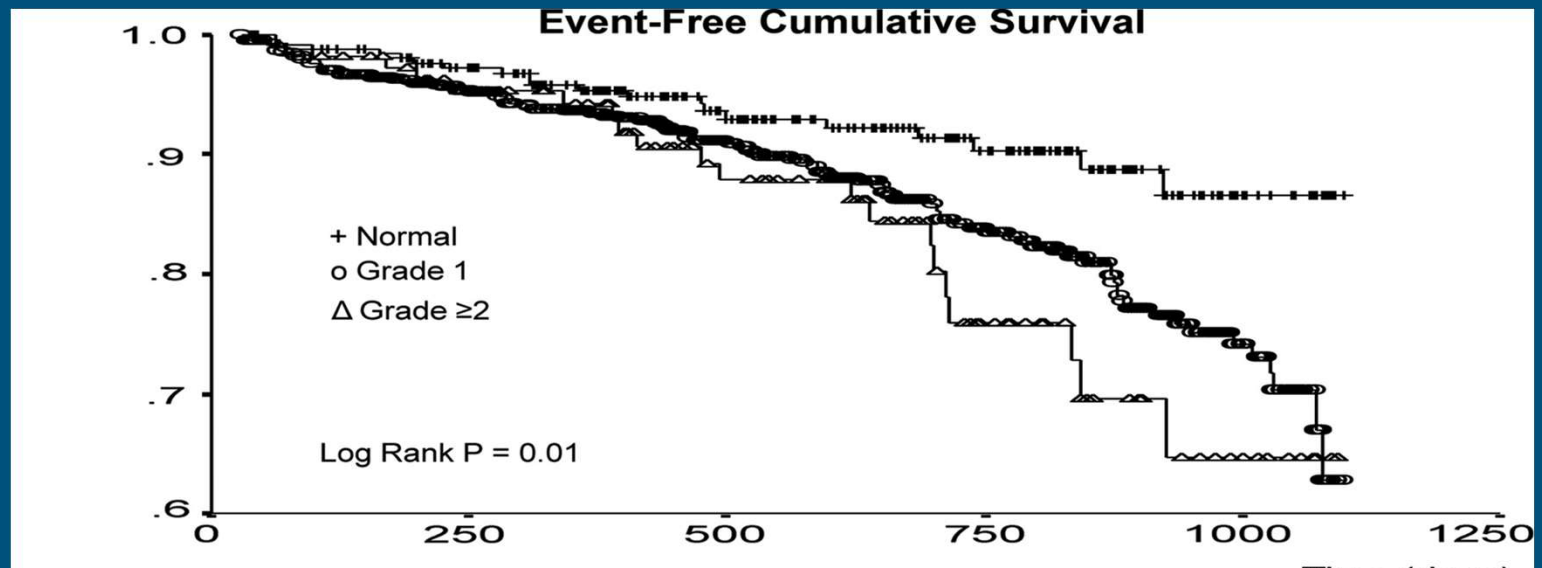

No. at risk					
Normal	264	225	145	85	21
Grade 1	689	577	406	230	73
≥Grade 2	112	93	63	31	8

No. of Deaths				
Normal	7	8	3	2
Grade 1	31	23	25	18
≥Grade 2	5	6	6	3

Diastolic Dysfunction:

- Doppler echocardiographic techniques:
  : offer high temporal resolution.

- Assess diastolic function and ventricular filling pressures :
  - Doppler mitral inflow dynamics and
  - Tissue Doppler (septal and lateral).

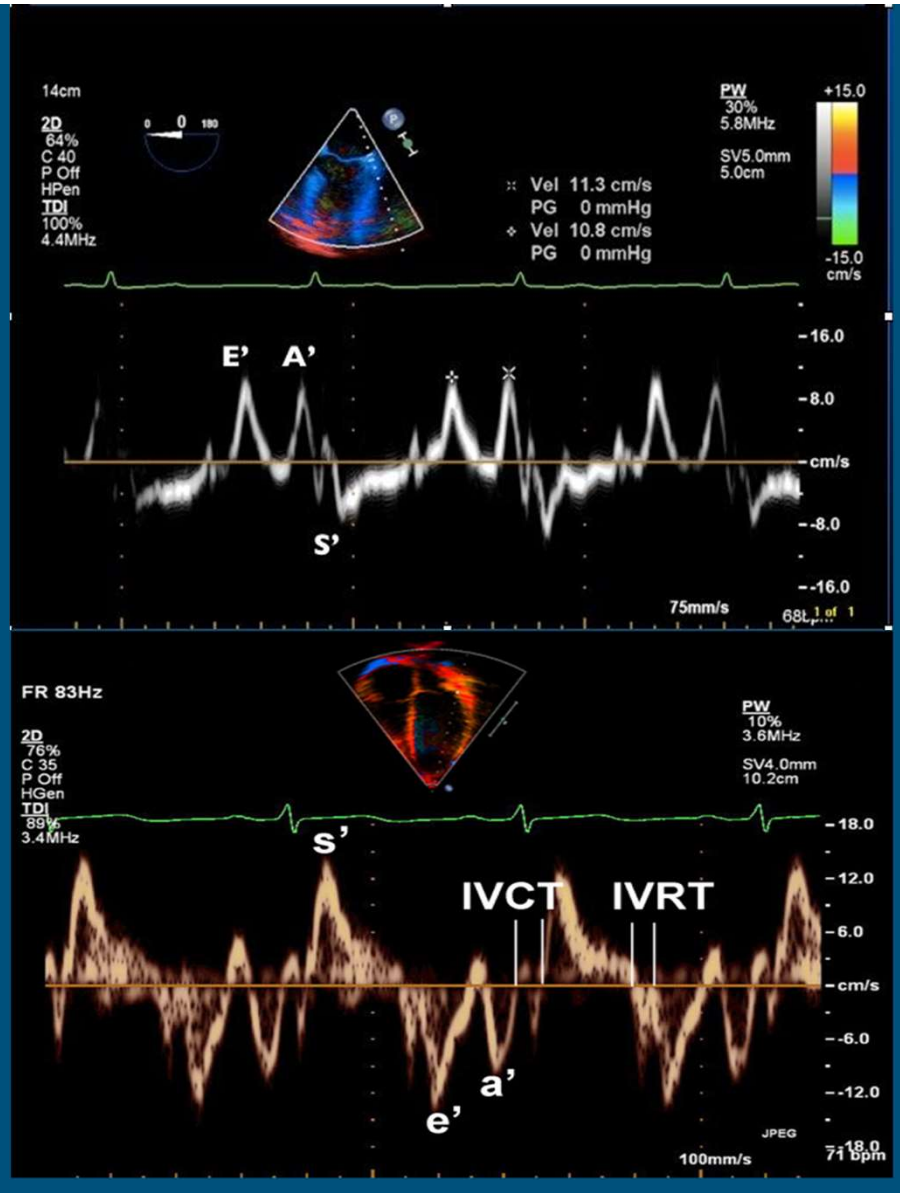

Strain Imaging: Echocardiogram

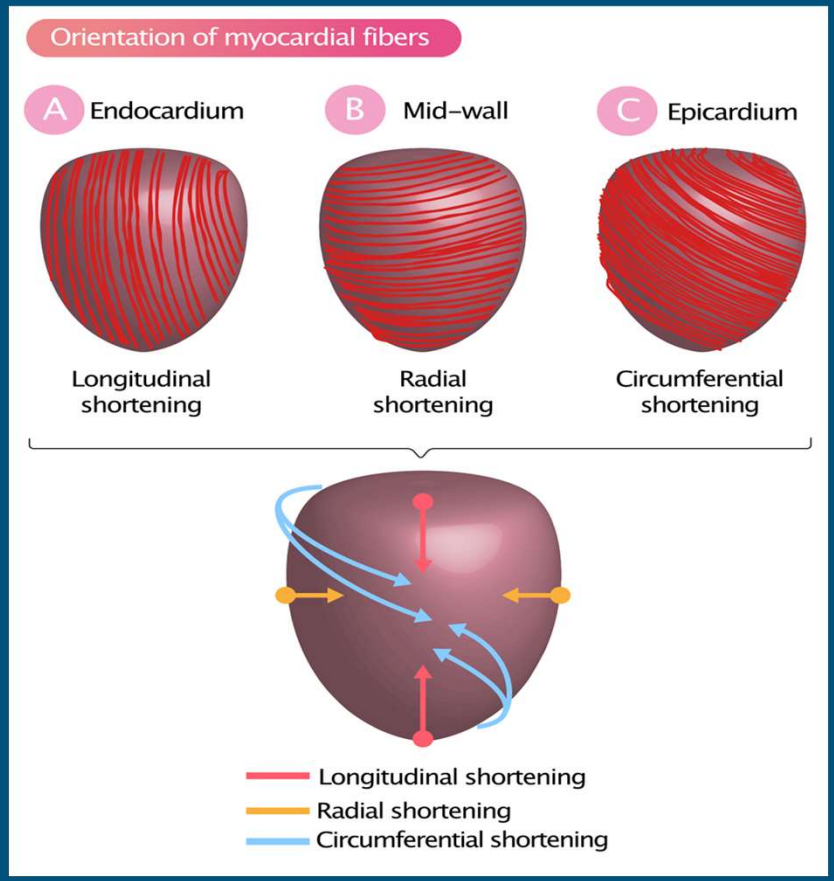

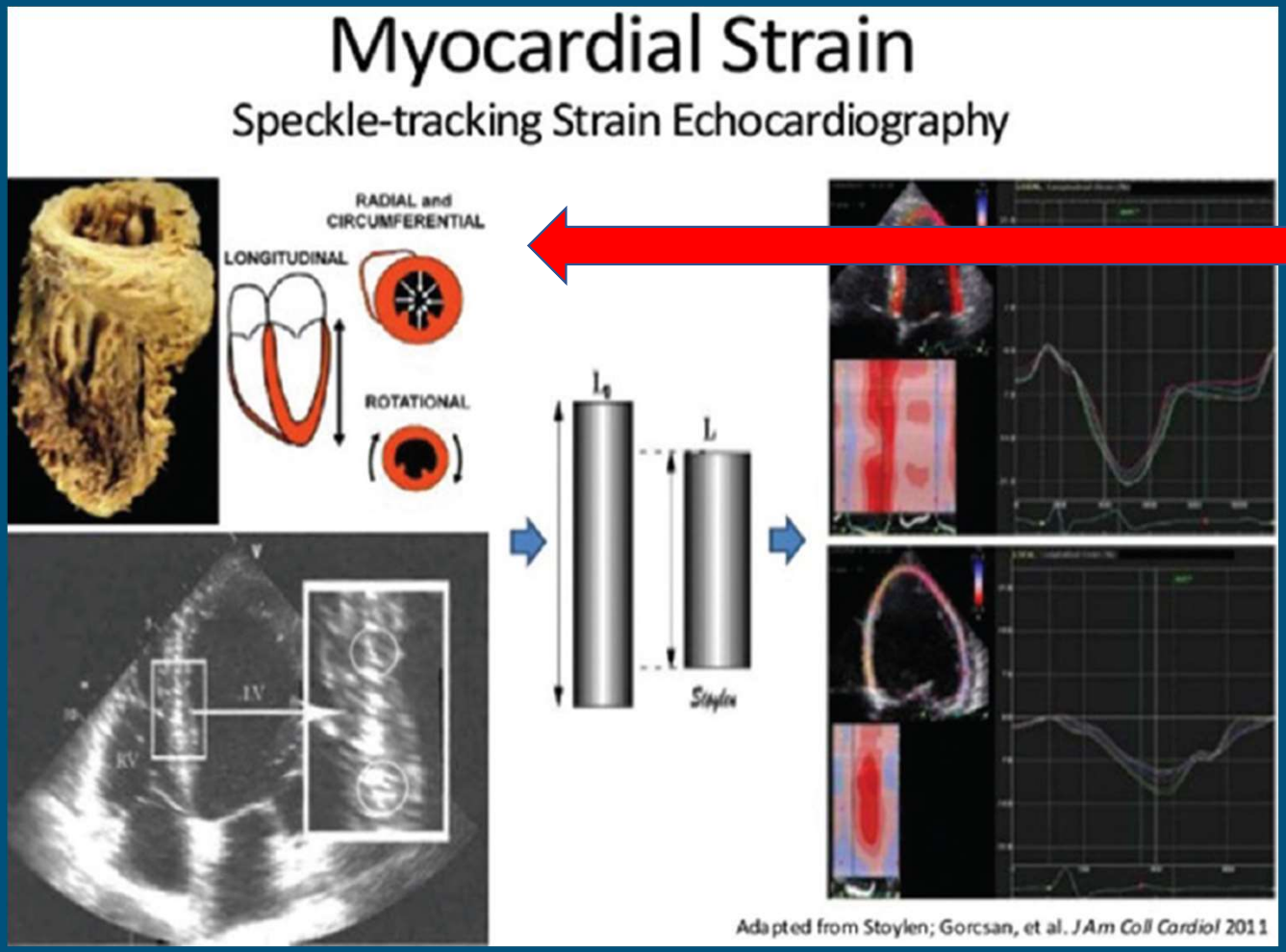

Radial
& Longitudinal

Regional & Global

Time to Peak strain

<u>Pathology</u>

ECHO STRAIN IMAGING: Myocardial

Perfusion:

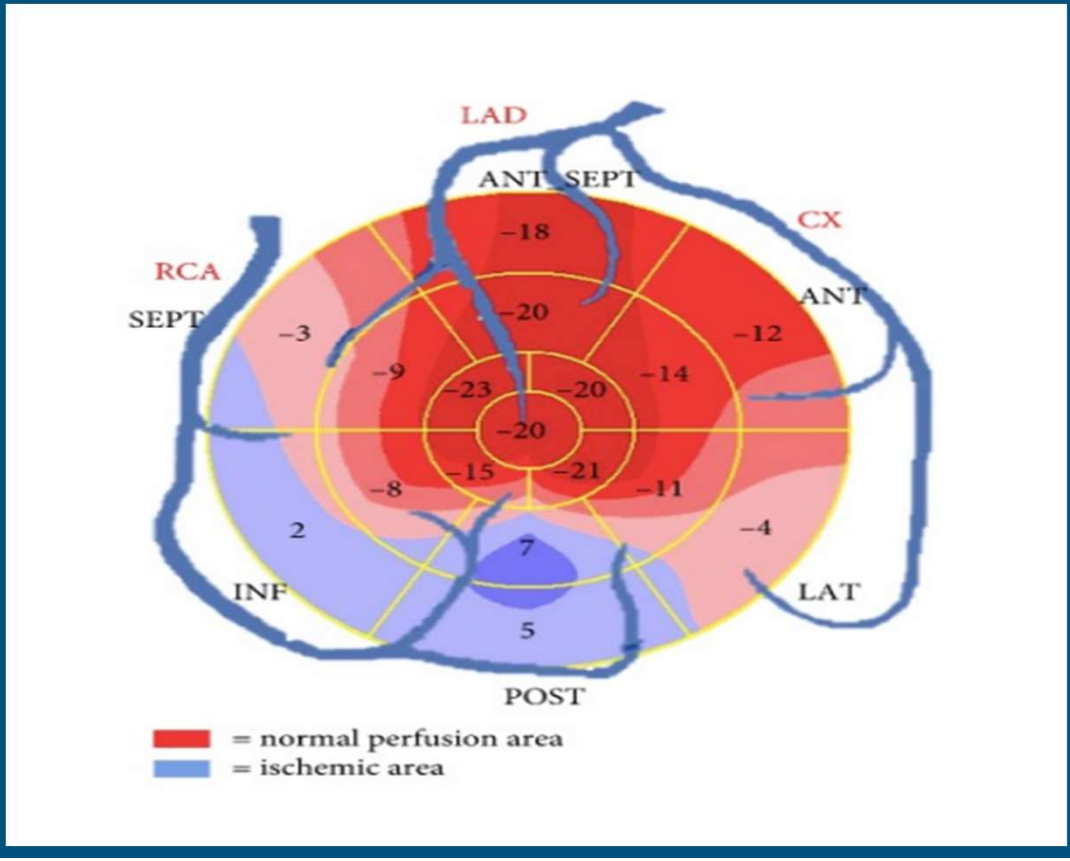

STRAIN IMAGING: SYSTOLIC FUNCTION

GLS and EF on Mortality

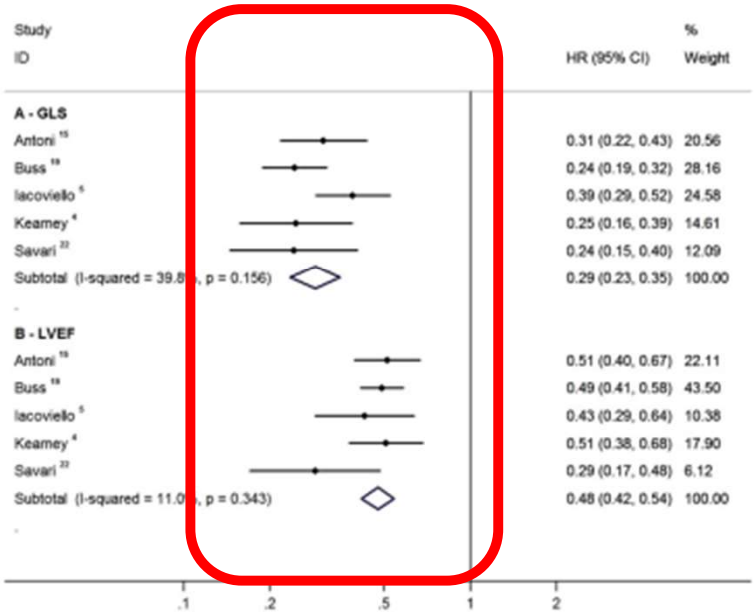

GLS and EF on Composite Endpoint

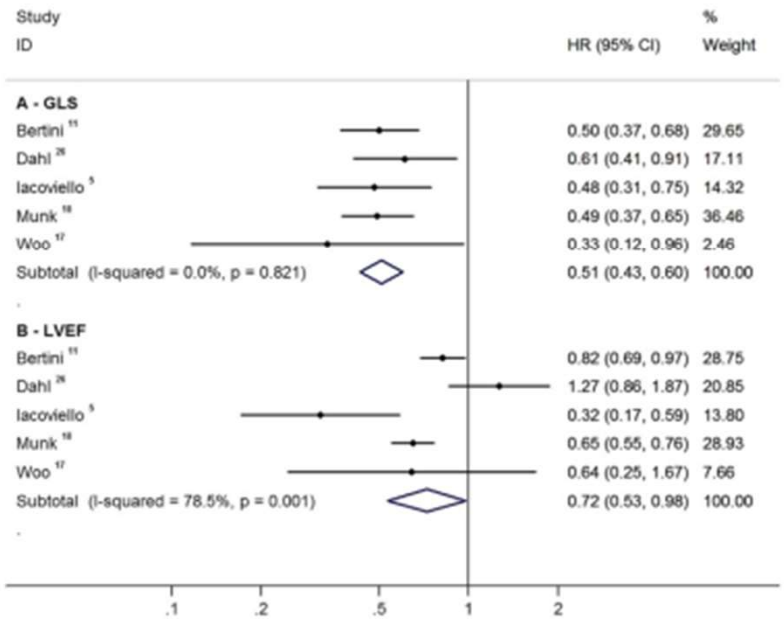

Cardiotoxic Chemo- agents/ Radiation

- Anthracyclines
- HER2 Inhibitors
- VEGF Inhibitors
- Bcr-Abl Kinase Inhibitors
- Proteasome Inhibitors
- Immune Checkpoint Inhibitors

EARLY DETECTION:

: Normal values< -18

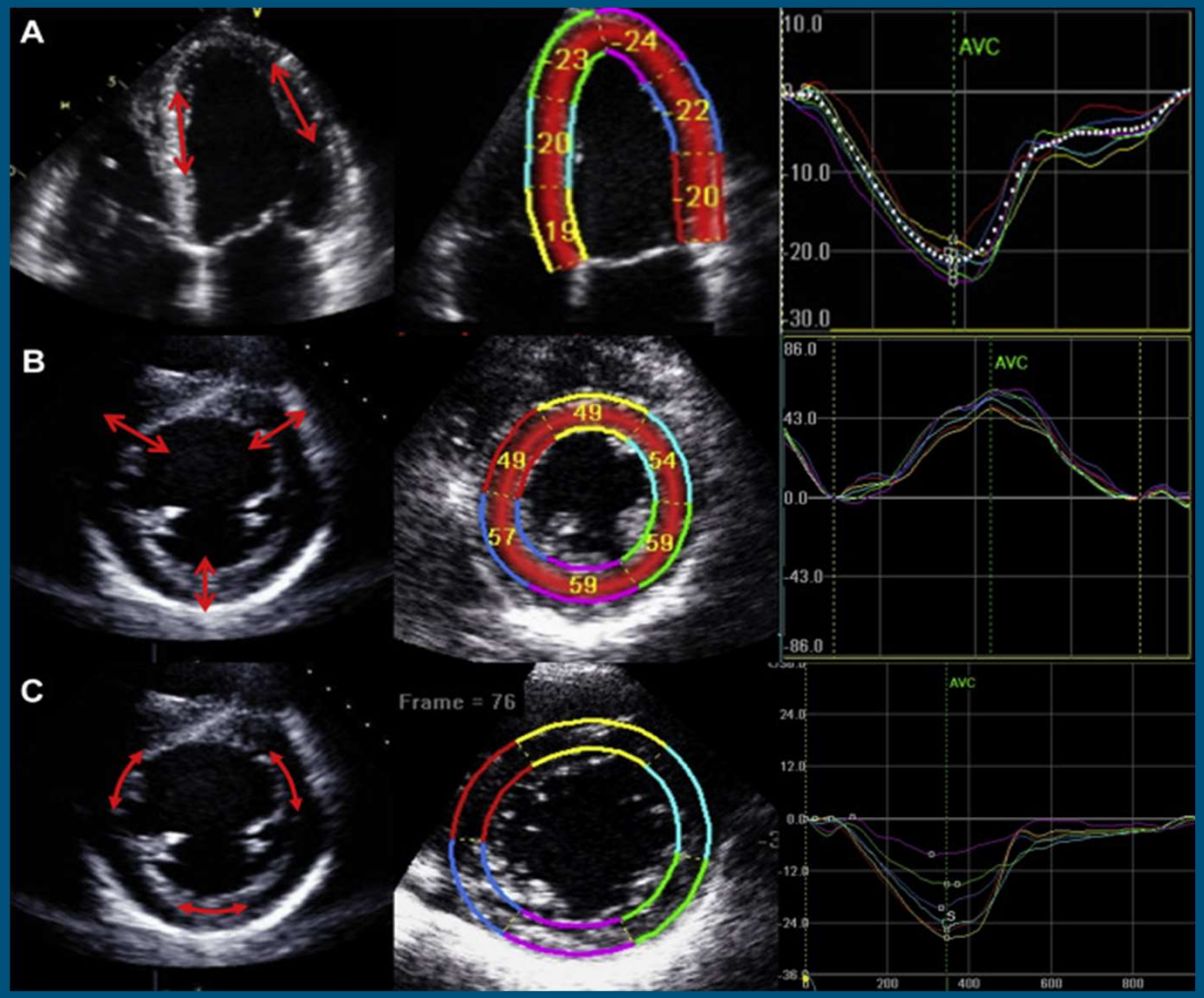



Other applications for Strain Imaging

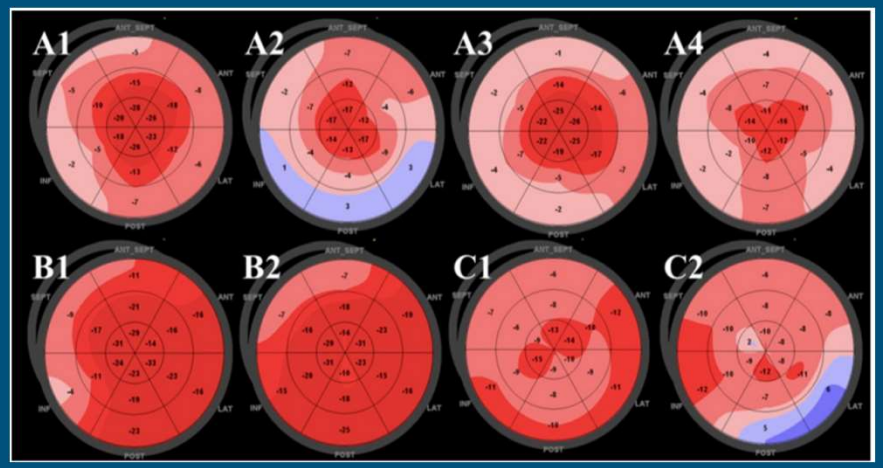

- Amyloidosis
- Undifferentiated LV Hypertrophy
- Valvular dysfunction: Aortic stenosis
- Ischemic Heart disease

Cardiac MRI: Current gold standard

: Chamber quantification
: Volumes
: Ejection fraction

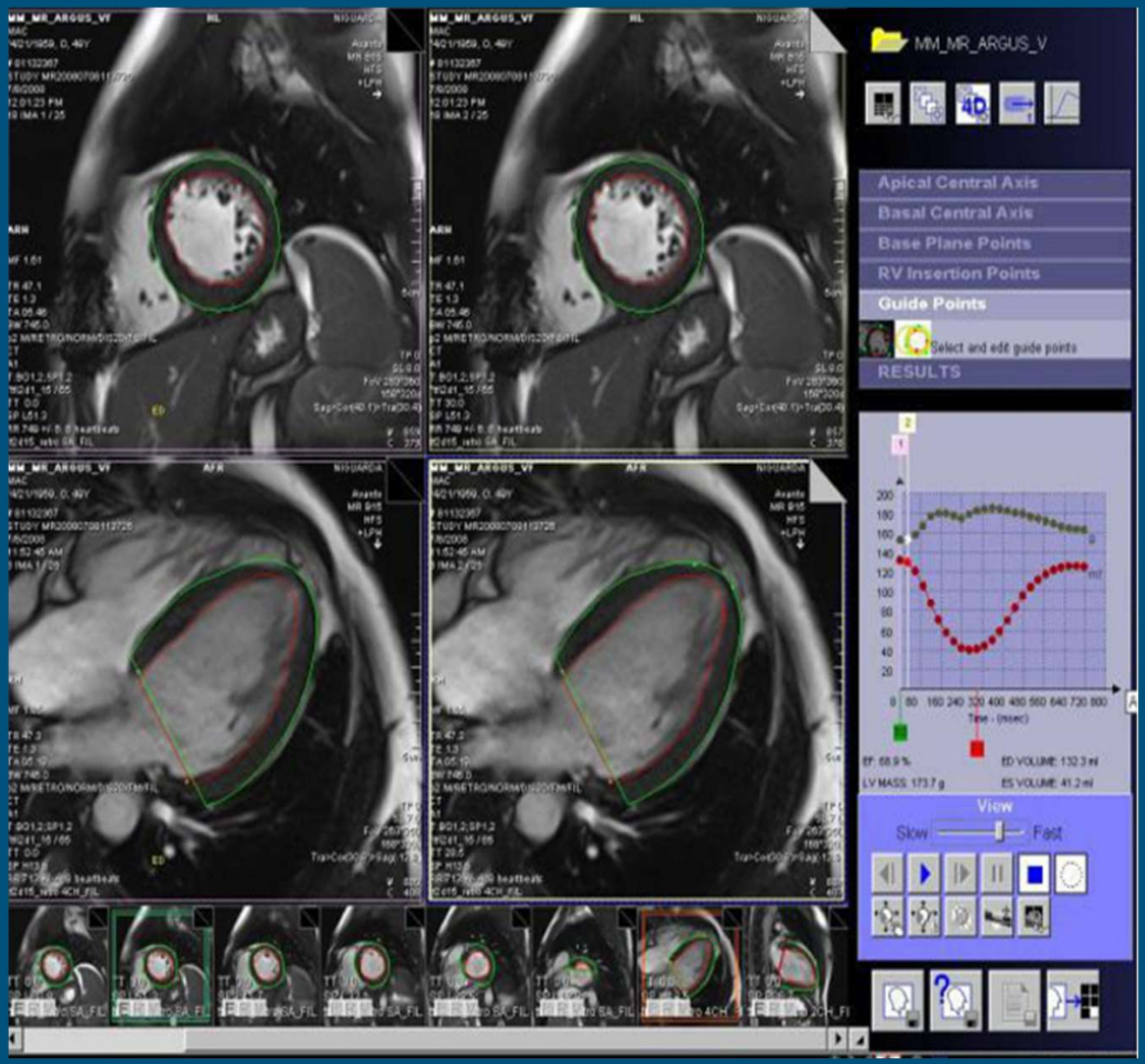

Cardiac MR in CARDIOMYOPATHIES

- CLINICAL USES:
  - Ischemic /Non ischemic
  - Acute Myocarditis
  - Hypertrophic cardiomyopathy
  - Ventricular Non compaction
  - Arrhythmogenic cardiomyopathy
  - Cardiac sarcoidosis
  - Cardiac Amyloidosis
  - Myocardial siderosis

- IMAGING TECHNIQUES:
  - Cardiac Volume/ mass and function (Cine imaging)
  - Cardiac structure and anatomy (static imaging)
  - Tissue characterizations
    - Late gadolinium enhancement
    - T1,T2,T3, Fat saturation
  - Resting perfusion

Cardiac MRI:
late gadolinium enhancement Patterns

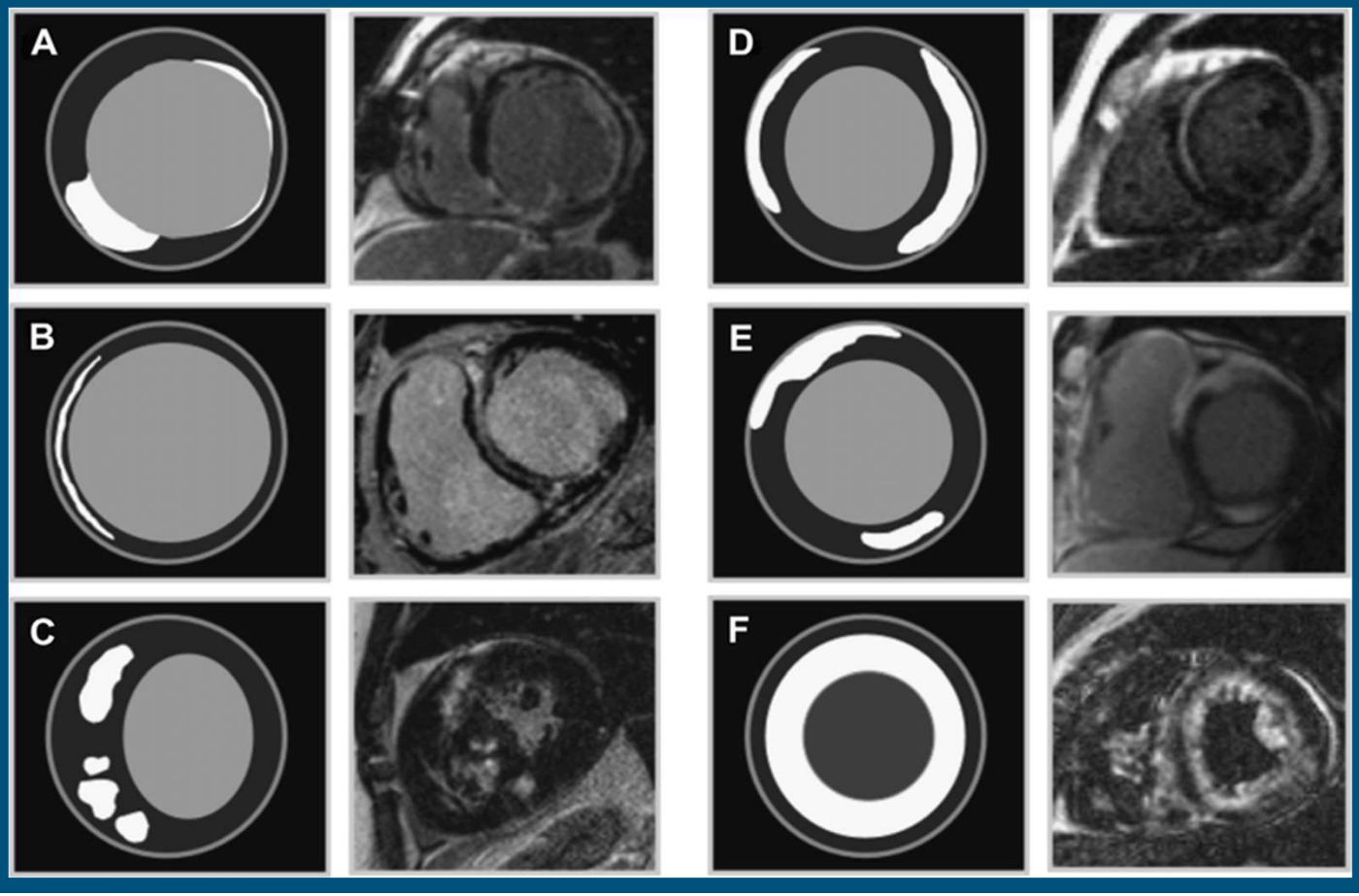

- Ischemic /Non ischemic
- Acute Myocarditis
- HOCM
- Non compaction
- ARVC
- Sarcoidosis
- Amyloidosis
- Myocardial siderosis

Cardiac Imaging in Coronary Artery Disease

- The standard for detecting ischemia with noninvasive imaging techniques has been :
  - Stress testing with echocardiography and nuclear perfusion techniques.

- Cardiac MRI : Perfusion
- Calcium scoring
- Coronary CT Angiography

Identifying Total Cardiovascular Risk

- Ischemia and Heart failure (Low EF)

Shift of focus to Total Cardiovascular Ris

- Risk assessment by identifying the phenotype :
  - Coronary calcium/ atherosclerosis
  - Left ventricular hypertrophy and
  - Diastolic dysfunction.

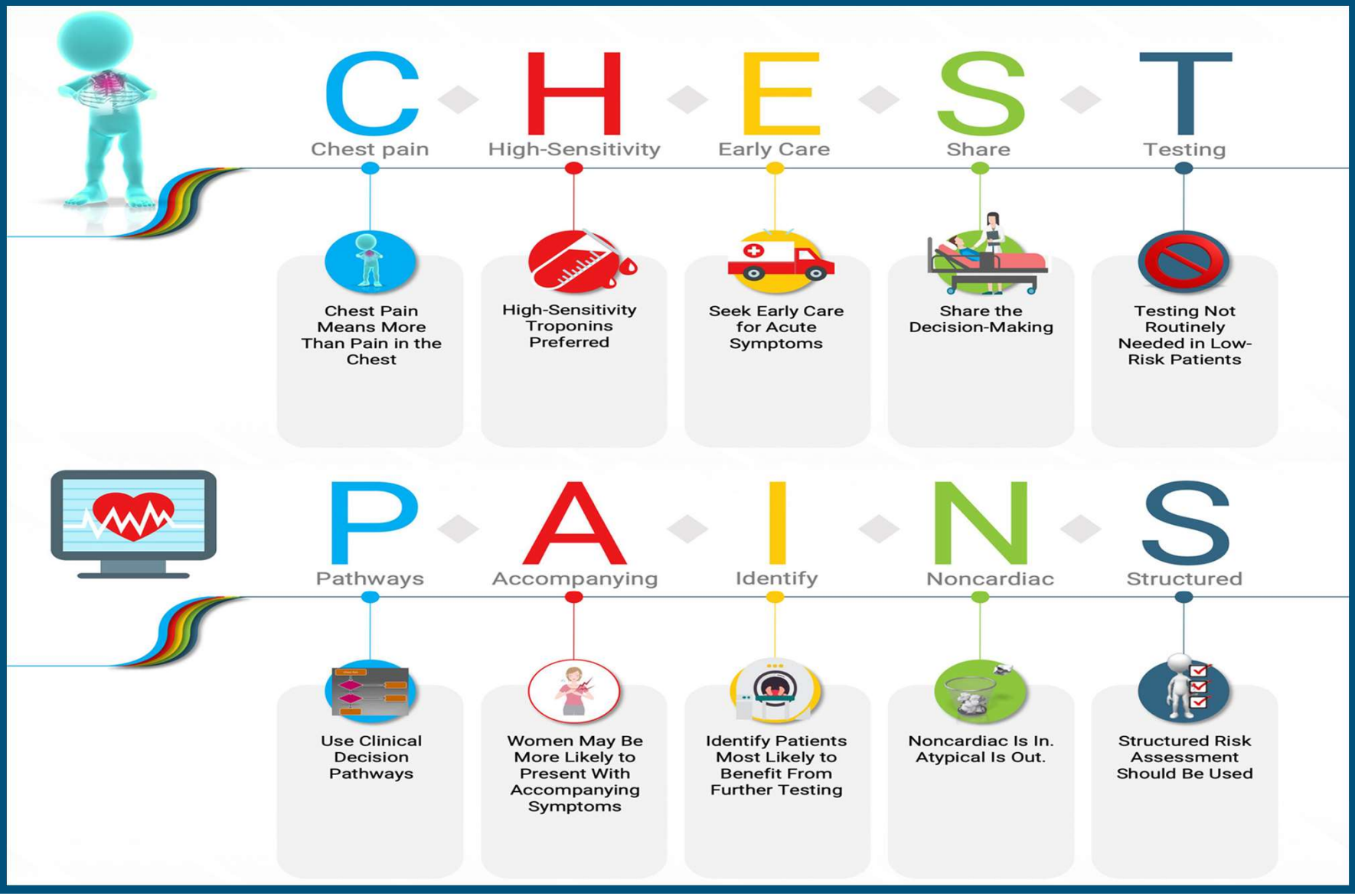
C
Chest pain
Chest Pain Means More Than Pain in the Chest
H
High-Sensitivity
High-Sensitivity Troponins Preferred
E
Early Care
Seek Early Care for Acute Symptoms
S
Share
Share the Decision-Making
T
Testing
Testing Not Routinely Needed in Low-Risk Patients
P
Pathways
Use Clinical Decision Pathways
A
Accompanying
Women May Be More Likely to Present With Accompanying Symptoms
I
Identify
Identify Patients Most Likely to Benefit From Further Testing
N
Noncardiac
Noncardiac Is In. Atypical Is Out.
S
Structured
Structured Risk Assessment Should Be Used

Calcium score:

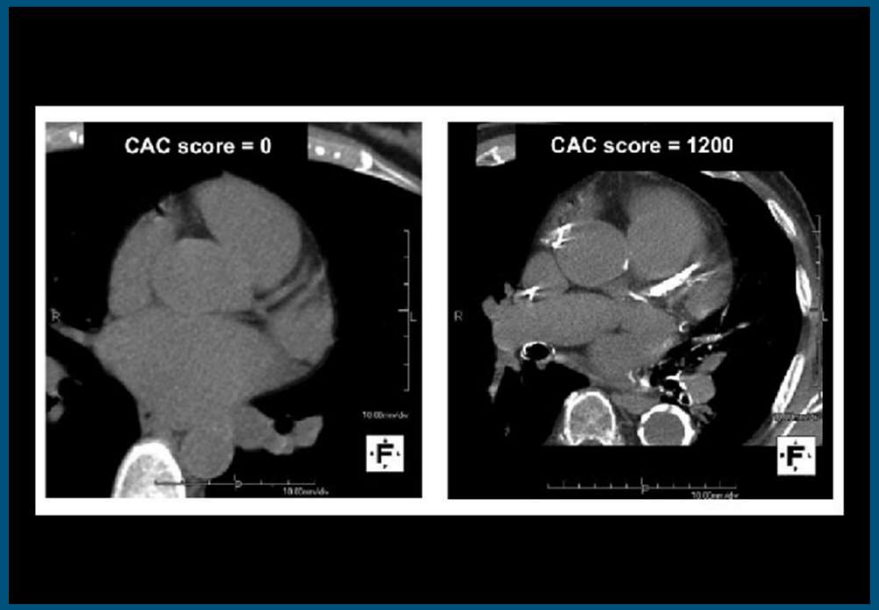

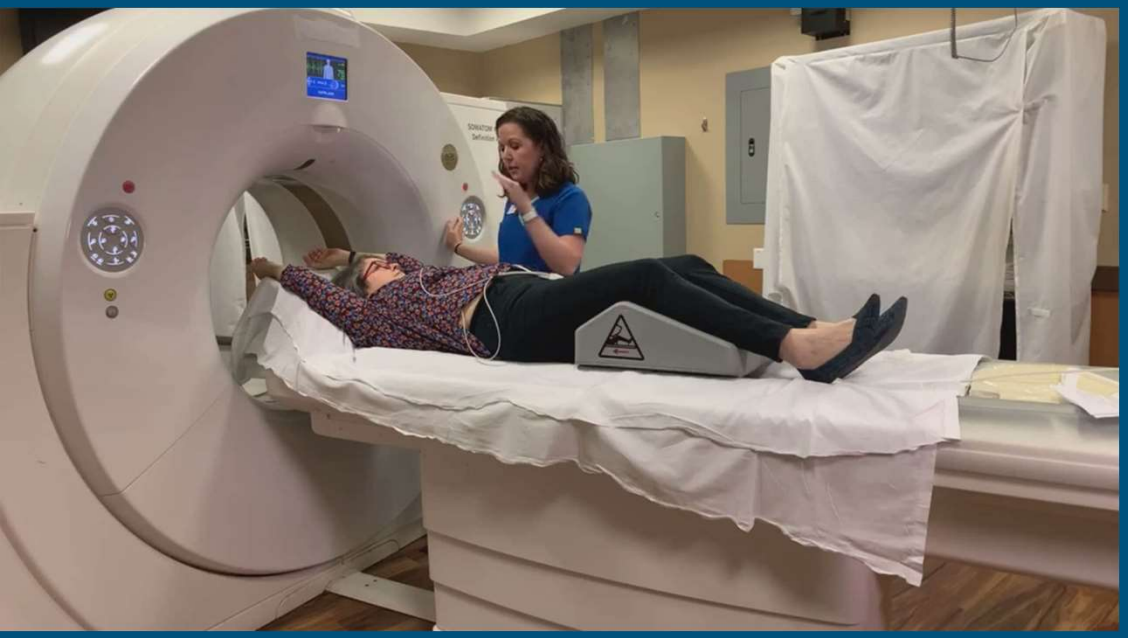

Increasing CAC predict Mortality!

-Budoff et al JACC 2007

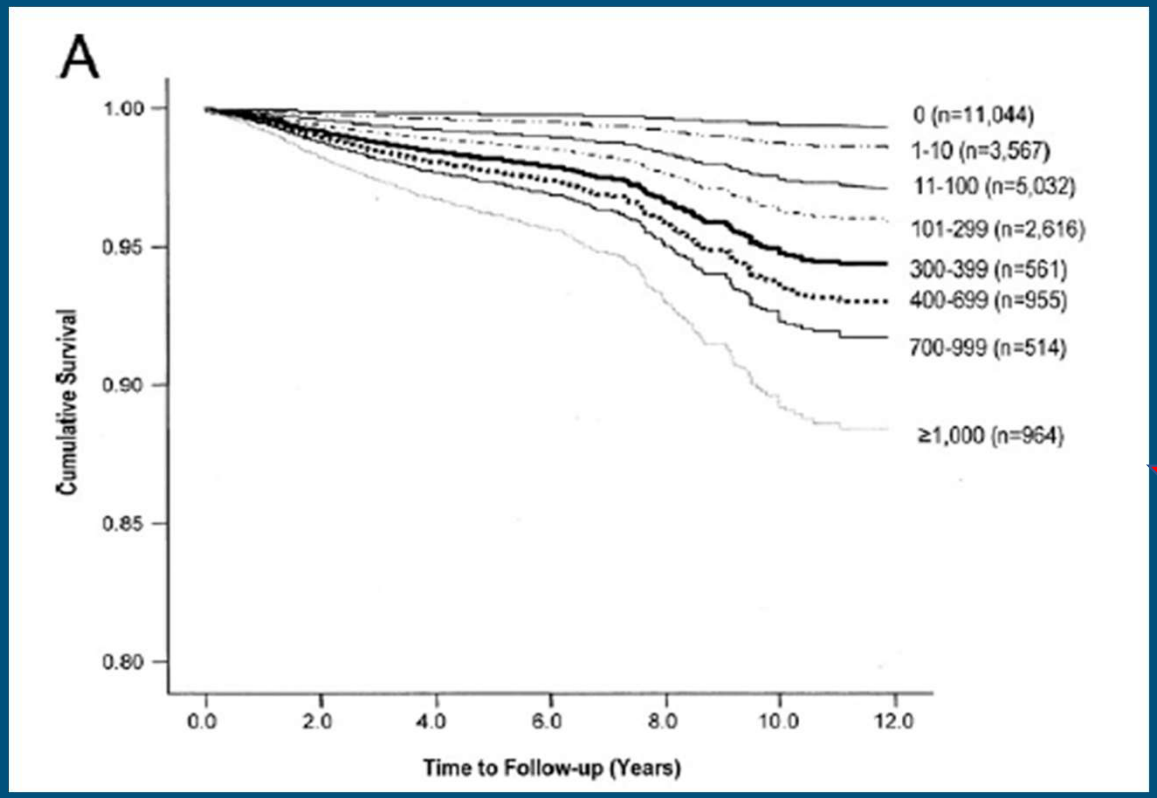

Higher the Ca score,
Higher the mortality risk

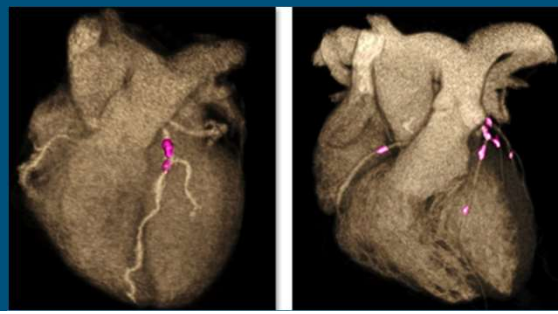

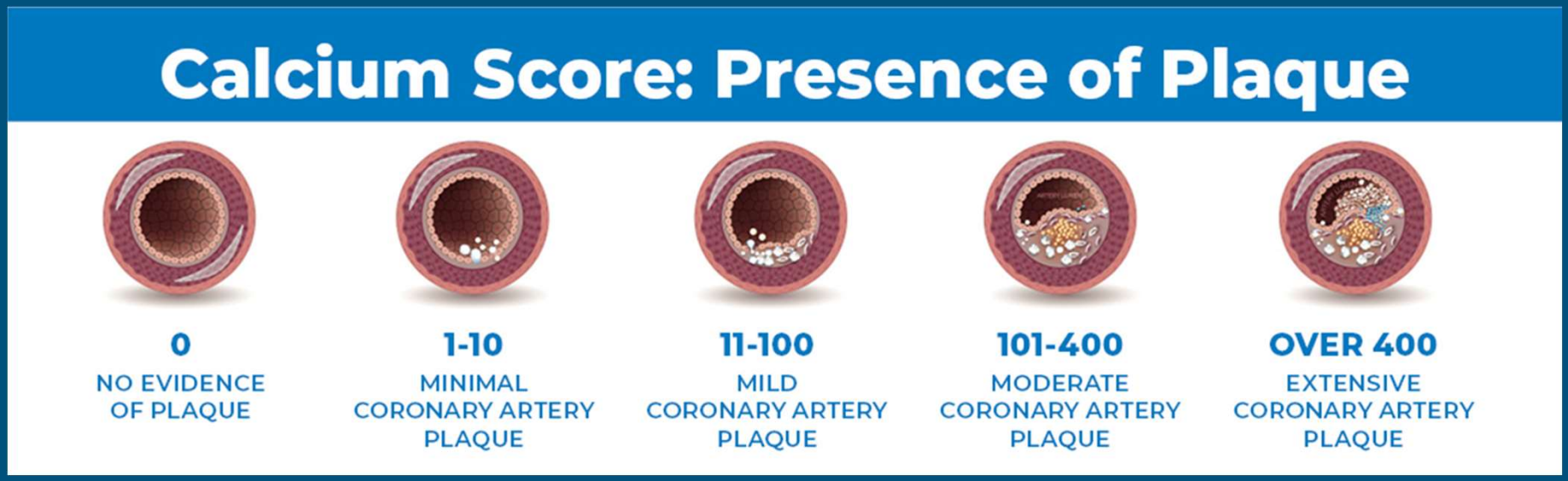

PRIMARY PREVENTION:
ASPIRIN. STATIN

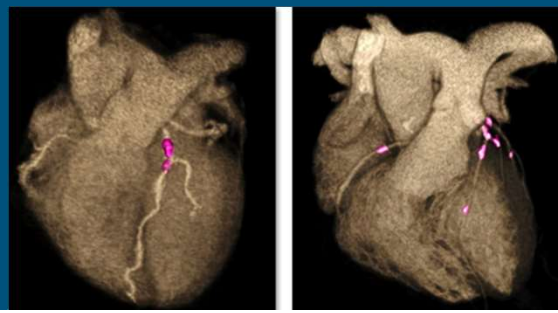

Suggested Algorithm for use of CAC scoring

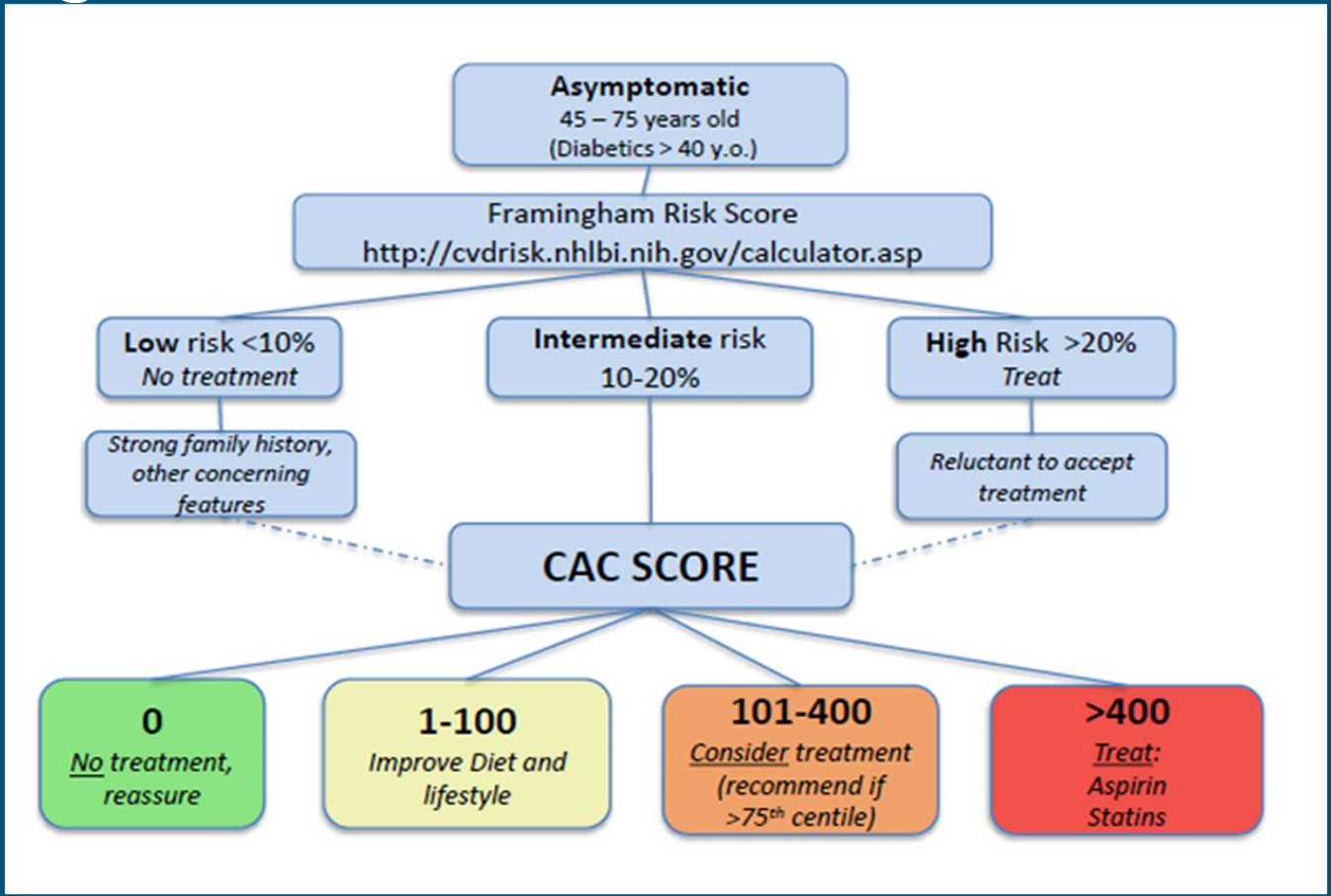

CORONARY CT ANGIOGRAM

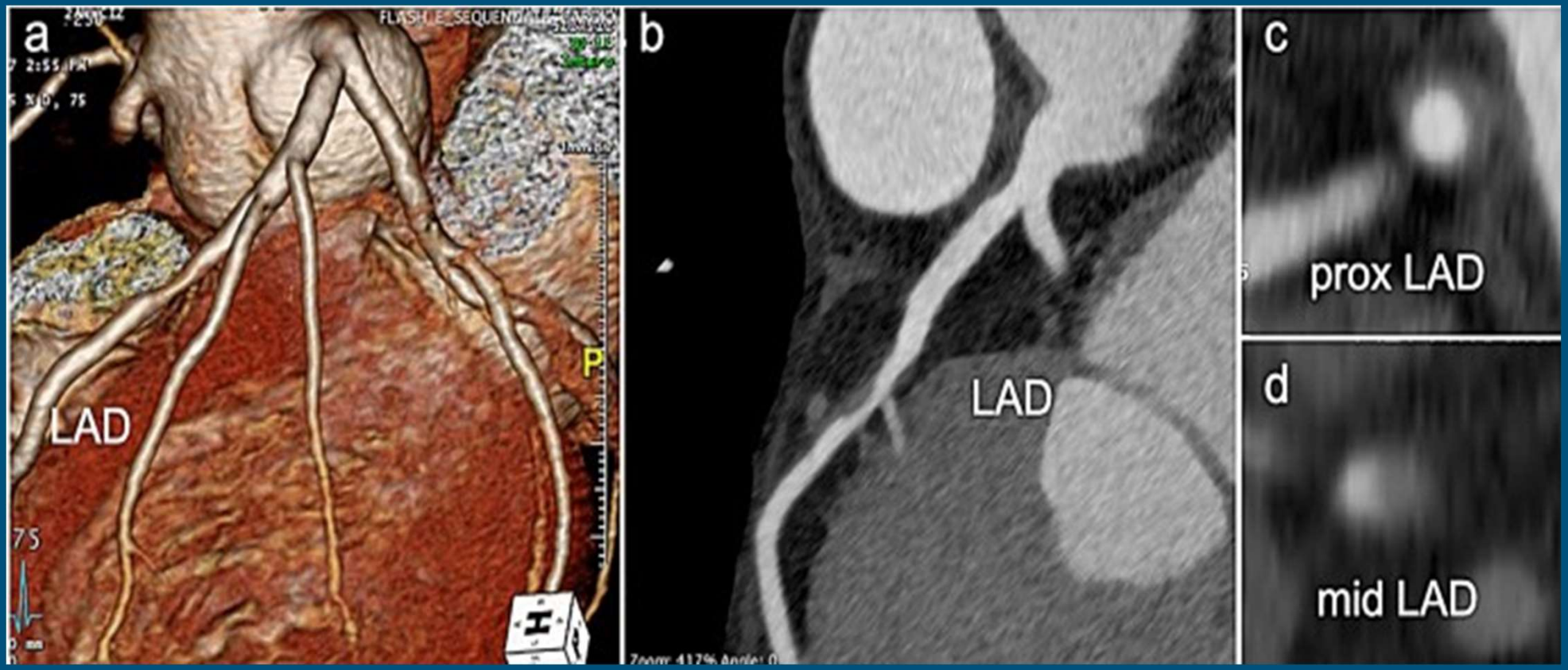

Applications of CCTA

- Emerging as a first-line diagnostic modality for coronary artery disease (CAD) in ED/ Clinic/ Pre Op: cardiac status

- United Kingdom in 2016 and European Society of Cardiology.
- effective, safe, and rapid modality for ruling out CAD (JACC , 2020)

Circulation
Volume 141, Issue 18, 5 May 2020; Pages 1452-1462
https://doi.org/10.1161/CIRCULATIONAHA.119.044720

American Heart Association.

ORIGINAL RESEARCH ARTICLE

Low-Attenuation Noncalcified Plaque on Coronary Computed Tomography Angiography Predicts Myocardial Infarction

Results From the Multicenter SCOT-HEART Trial (Scottish Computed Tomography of the HEART)

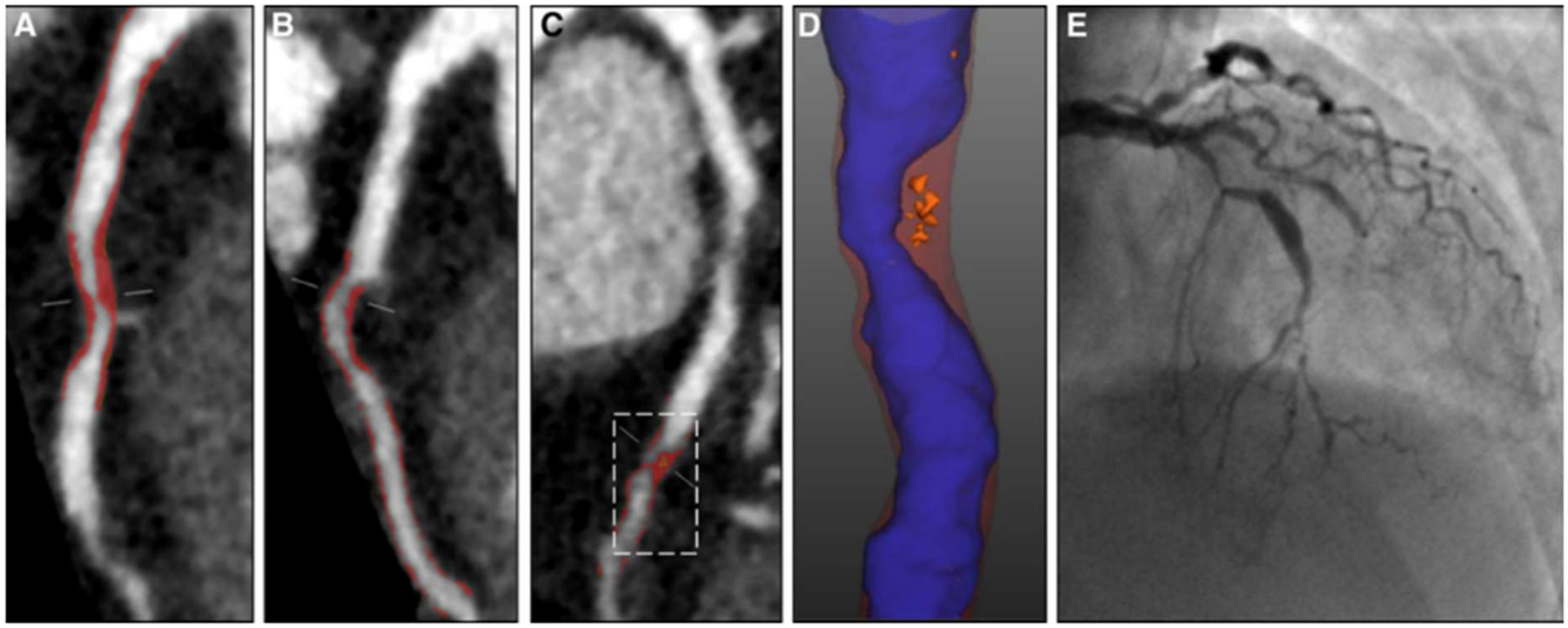

- Plaque volumes (in mm3)
- Total plaque, calcified plaque, noncalcified plaque and **low-attenuation plaque** (defined by an attenuation of <30 Hounsfield units [HU]).

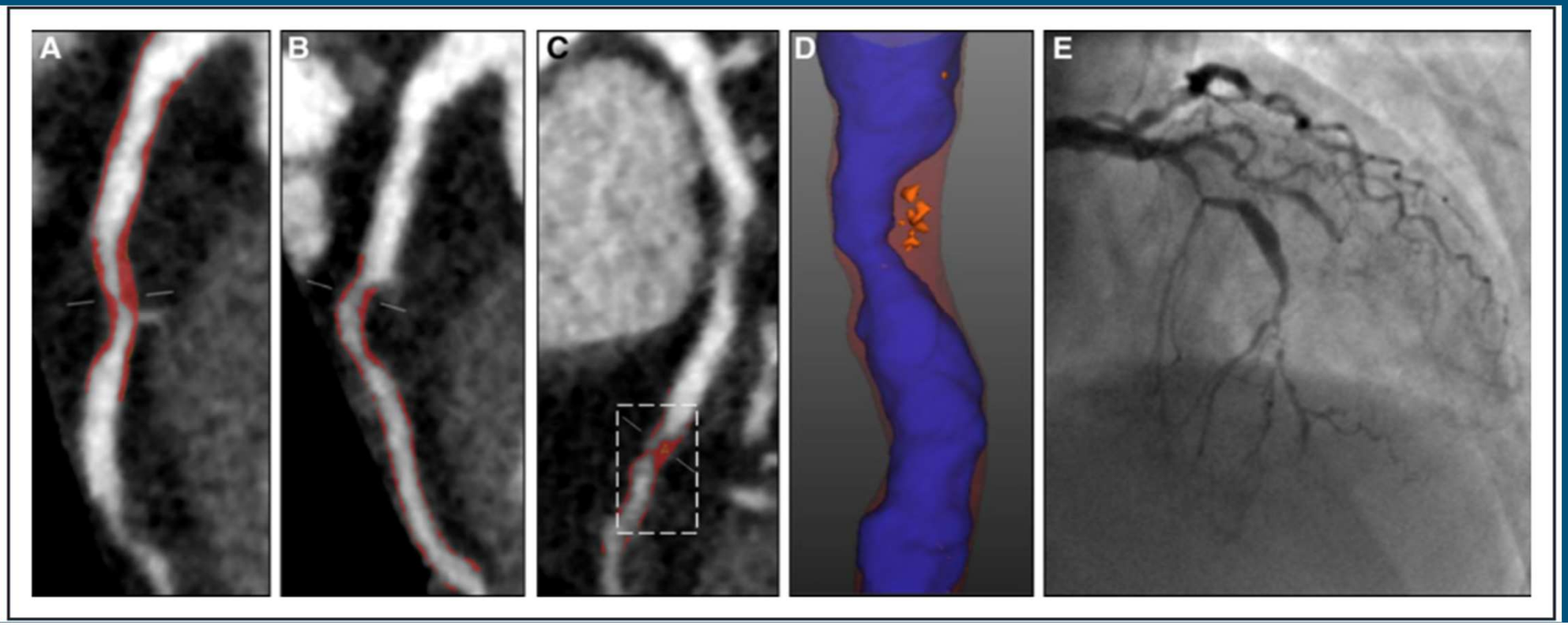

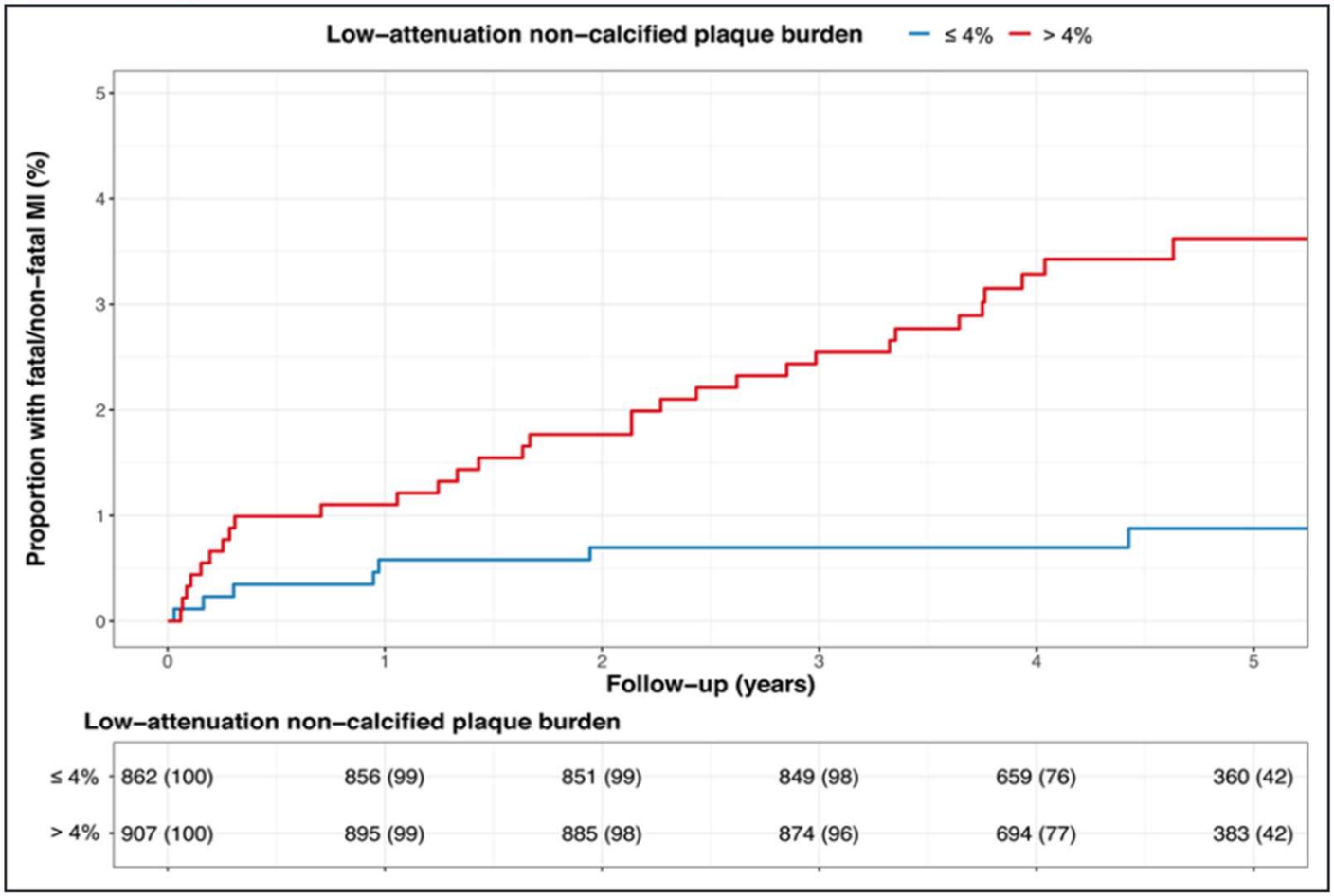

Figure 5. Low-attenuation plaque burden and fatal or nonfatal myocardial infarction. Cumulative incidence of fatal or nonfatal myocardial infarction in patients with and without a low-attenuation plaque burden greater than 4%. MI indicates myocardial infarction.

CCTA:

Disadvantages include :

reduced image quality in patients with morbid obesity,

dense calcifications,

Artifacts with : multiple or small-diameter stents, elevated heart rates, or arrhythmia;

the need for intravenous contrast, which may be nephrotoxic;

and the risk of excess downstream testing.

FFR CT: Flow *functional* reserve

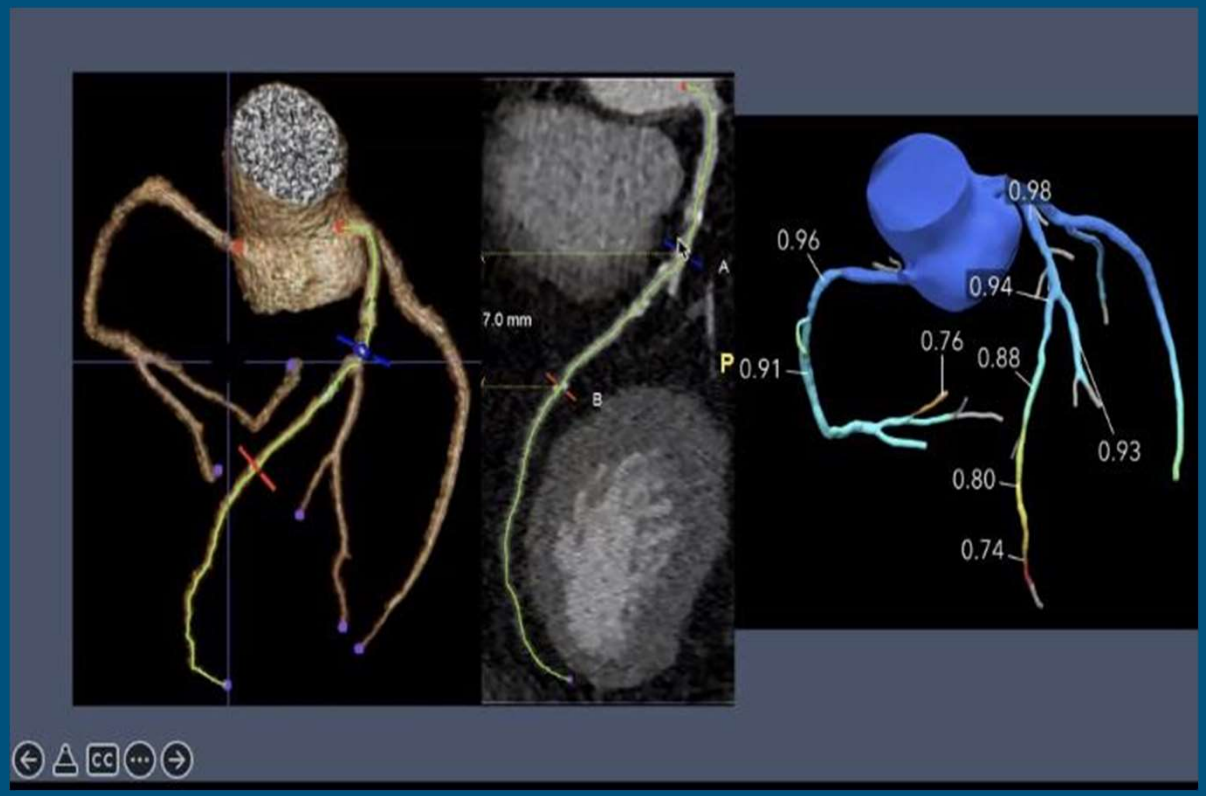

- provides an anatomical and functional assessment. ”
- “fluid dynamics-based CT FFR ……..detecting lesion-specific ischemia, especially in intermediate lesions”

Method for computation of FFR_{CT}

Coronary CTA data set

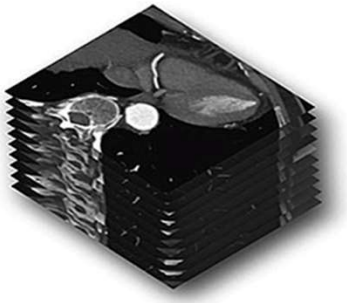

Anatomic model of coronaries

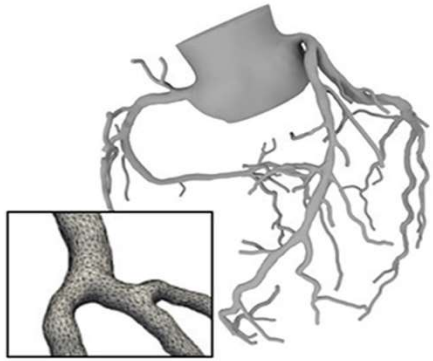

Physiologic model of circulation

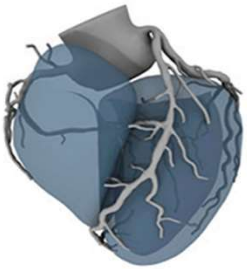

Modeling maximal hyperaemia

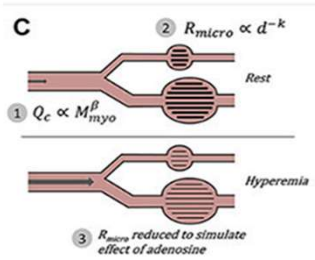

Computation of coronary flow

Mass Conservation (1 equation):

$$\frac{\partial v_x}{\partial x} + \frac{\partial v_y}{\partial y} + \frac{\partial v_z}{\partial z} = 0$$

Momentum Balance (3 equations):

$$\rho \frac{\partial v_x}{\partial t} + \rho\left(v_x \frac{\partial v_x}{\partial x} + v_y \frac{\partial v_x}{\partial y} + v_z \frac{\partial v_x}{\partial z}\right) = -\frac{\partial p}{\partial x} + \mu\left(\frac{\partial^2 v_x}{\partial x^2} + \frac{\partial^2 v_y}{\partial y^2} + \frac{\partial^2 v_z}{\partial z^2}\right)$$

$$\rho \frac{\partial v_y}{\partial t} + \rho\left(v_x \frac{\partial v_y}{\partial x} + v_y \frac{\partial v_y}{\partial y} + v_z \frac{\partial v_y}{\partial z}\right) = -\frac{\partial p}{\partial y} + \mu\left(\frac{\partial^2 v_x}{\partial x^2} + \frac{\partial^2 v_y}{\partial y^2} + \frac{\partial^2 v_z}{\partial z^2}\right)$$

$$\rho \frac{\partial v_z}{\partial t} + \rho\left(v_x \frac{\partial v_z}{\partial x} + v_y \frac{\partial v_z}{\partial y} + v_z \frac{\partial v_z}{\partial z}\right) = -\frac{\partial p}{\partial z} + \mu\left(\frac{\partial^2 v_x}{\partial x^2} + \frac{\partial^2 v_y}{\partial y^2} + \frac{\partial^2 v_z}{\partial z^2}\right)$$

3-D FFR_{CT} solution

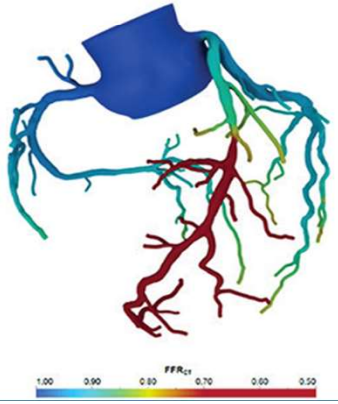

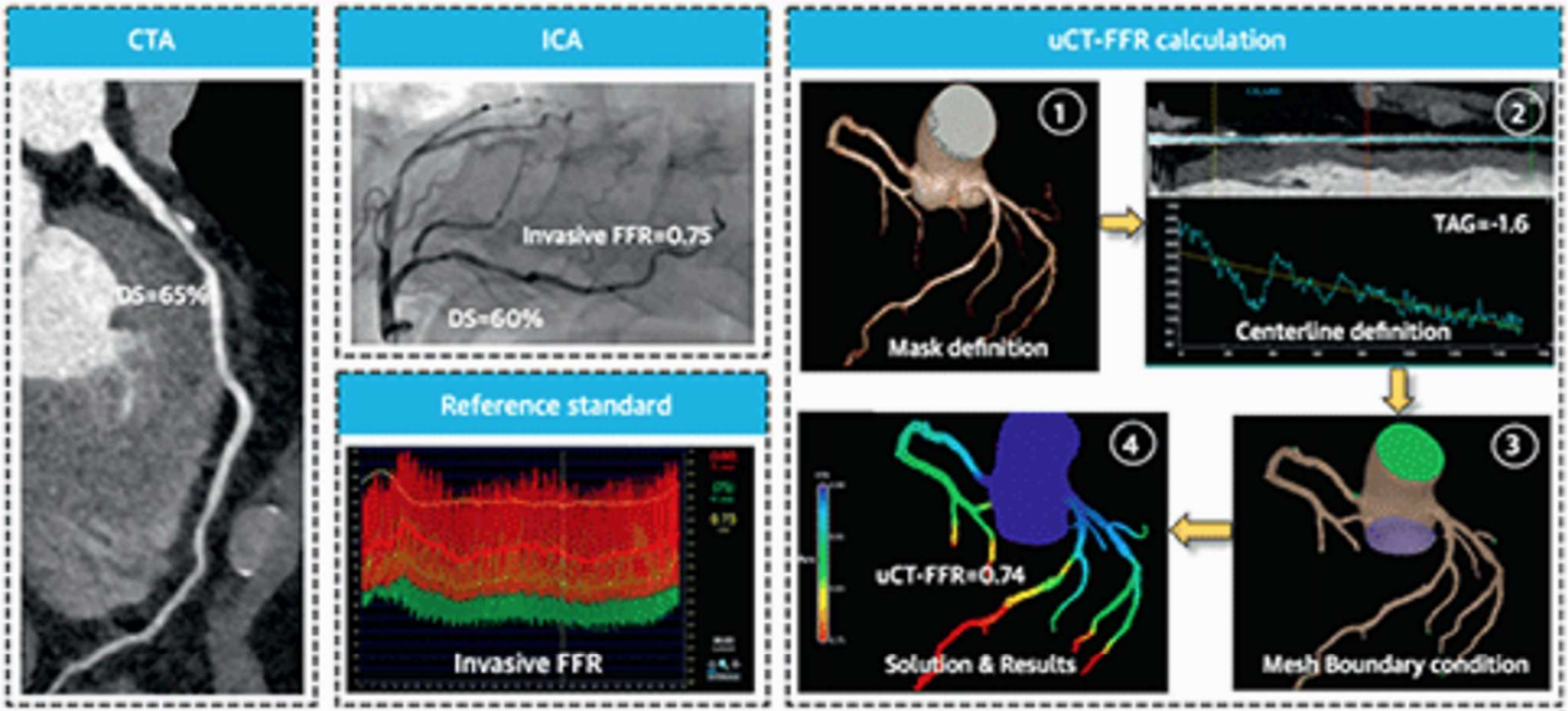

Parameters	CTA	ICA	uCT-FFR	P value	Post-Hoc
Sen.	0.92	0.94	0.89	0.195	-
Spec.	0.34	0.37	0.91	<0.001	CTA/ICA<uCT-FFR
Acc.	0.55	0.58	0.91	<0.001	CTA/ICA<uCT-FFR
AUC	0.75	0.66	0.92	<0.001	CTA/ICA<uCT-FFR

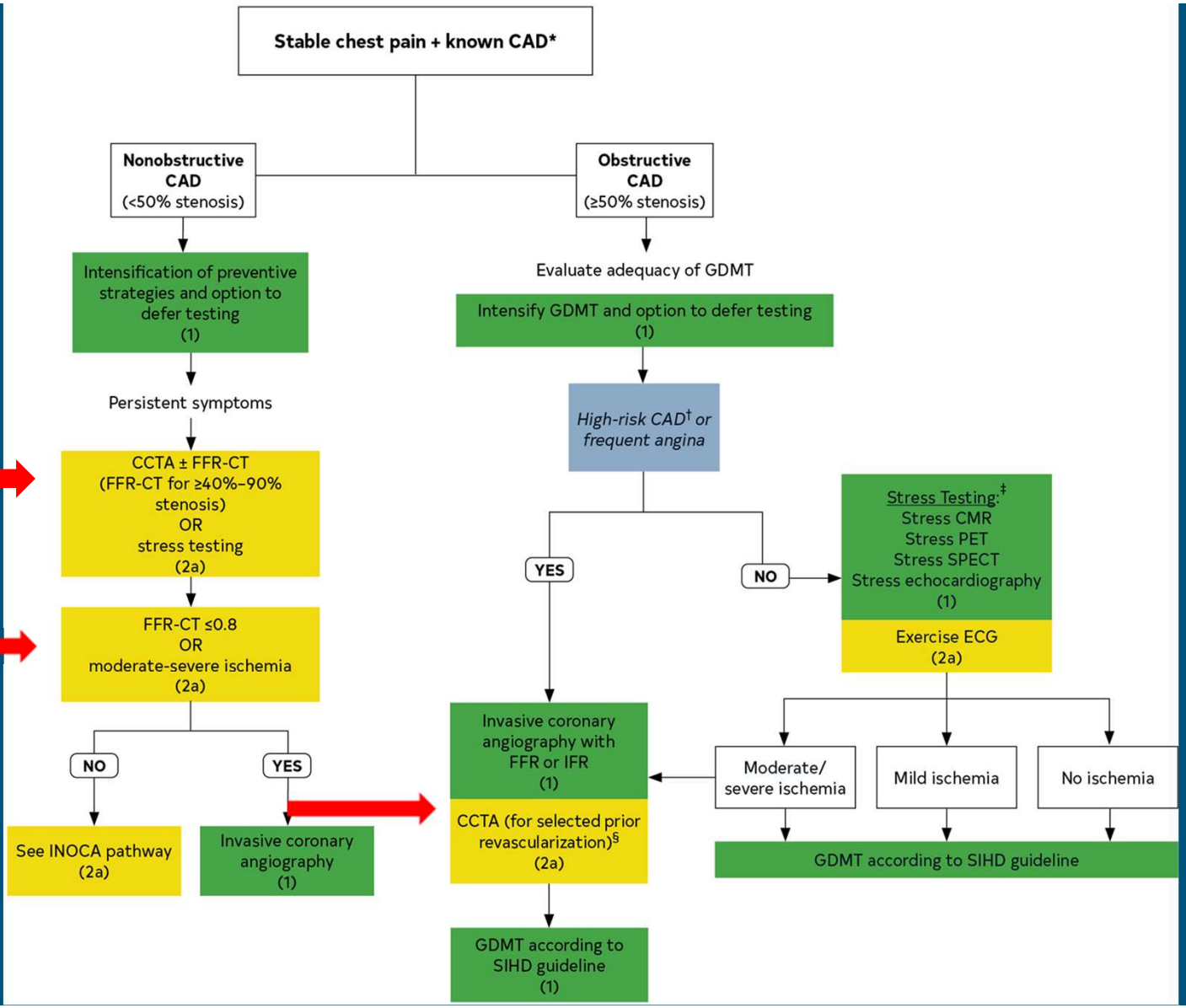

STABLE CHEST PAIN AND KNOWN CAD

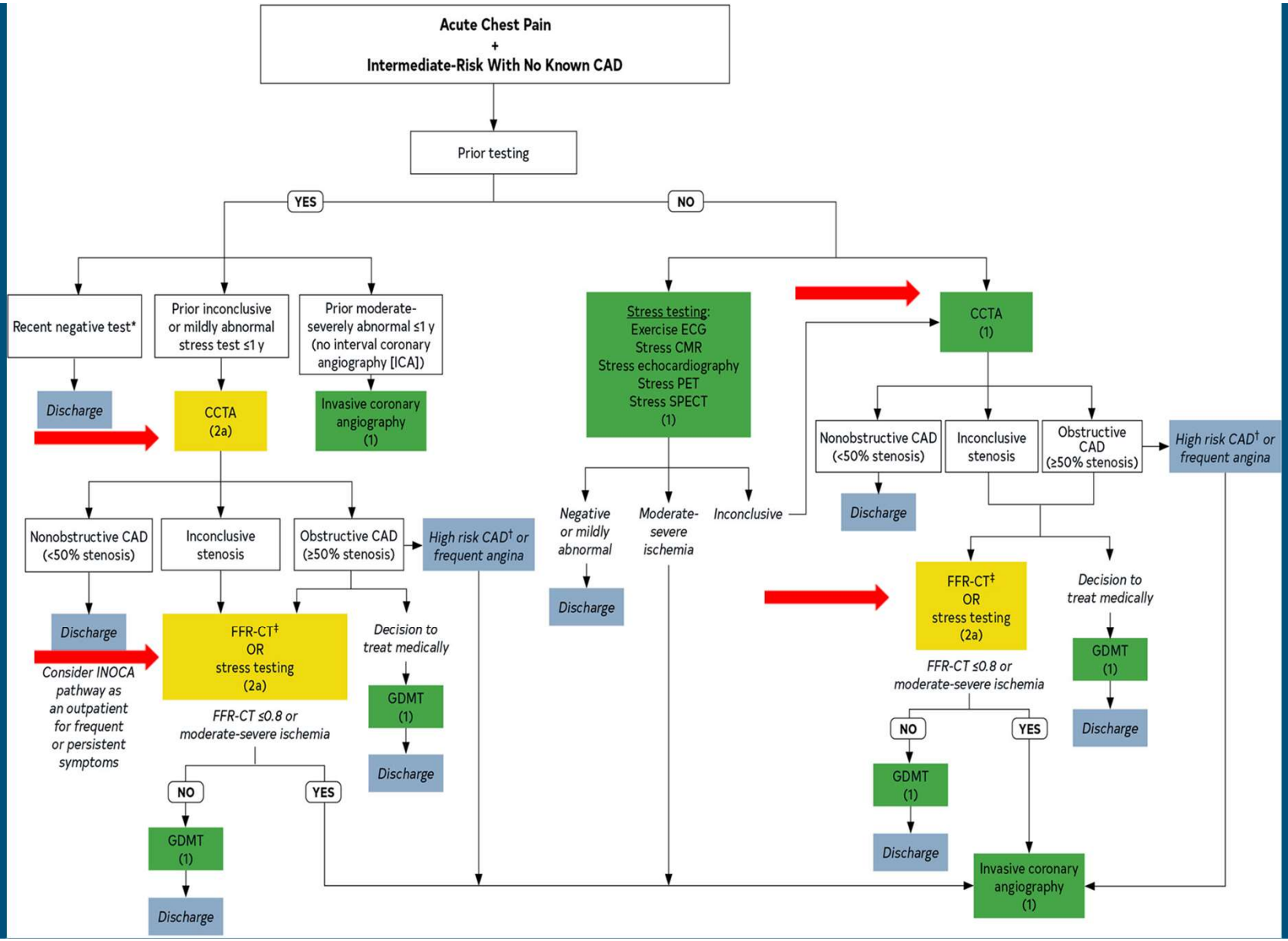
Acute Chest Pain
+
Intermediate-Risk With No Known CAD
Prior testing
YES
NO
Recent negative test*
Discharge
Prior inconclusive or mildly abnormal stress test ≤1 y
CCTA (2a)
Prior moderate-severely abnormal ≤1 y (no interval coronary angiography [ICA])
Invasive coronary angiography (1)
Nonobstructive CAD (<50% stenosis)
Discharge
Consider INOCA pathway as an outpatient for frequent or persistent symptoms
Inconclusive stenosis
FFR-CT‡ OR stress testing (2a)
FFR-CT ≤0.8 or moderate-severe ischemia
NO
YES
GDMT (1)
Discharge
Obstructive CAD (≥50% stenosis)
High risk CAD† or frequent angina
Decision to treat medically
GDMT (1)
Discharge
Stress testing: Exercise ECG Stress CMR Stress echocardiography Stress PET Stress SPECT (1)
Negative or mildly abnormal
Discharge
Moderate-severe ischemia
Inconclusive
CCTA (1)
Nonobstructive CAD (<50% stenosis)
Discharge
Inconclusive stenosis
Obstructive CAD (≥50% stenosis)
High risk CAD† or frequent angina
FFR-CT‡ OR stress testing (2a)
FFR-CT ≤0.8 or moderate-severe ischemia
NO
YES
GDMT (1)
Discharge
Decision to treat medically
GDMT (1)
Discharge
Invasive coronary angiography (1)

Cardiac testing and Radiation risk!

Examination	Mean effective dose
Background radiation	3 mSv/year
Chest X-ray	0.1 mSv
Calcium scoring	2 mSv
Chest CT	5–7 mSv
CT abdomen and Pelvis	8–11 mSv
Coronary angiography	5.6 mSv
PTCA	6.9 mSv
Coronary angiography with PTCA	9.3 mSv
Coronary Angiography + PTCA + Stent	13 mSv
SPECT-MIBI	11 mSv
SPECT-Thallium	25 mSv
Coronary CTA (males)	6.7–10.9 mSv
Coronary CTA (Females)	8.1–13.0 mSv



Interventional Imaging

- Transesophageal echo for placement of
  - TAVR & TEER

Transcather Aortic Valve Replacement (TAVR)

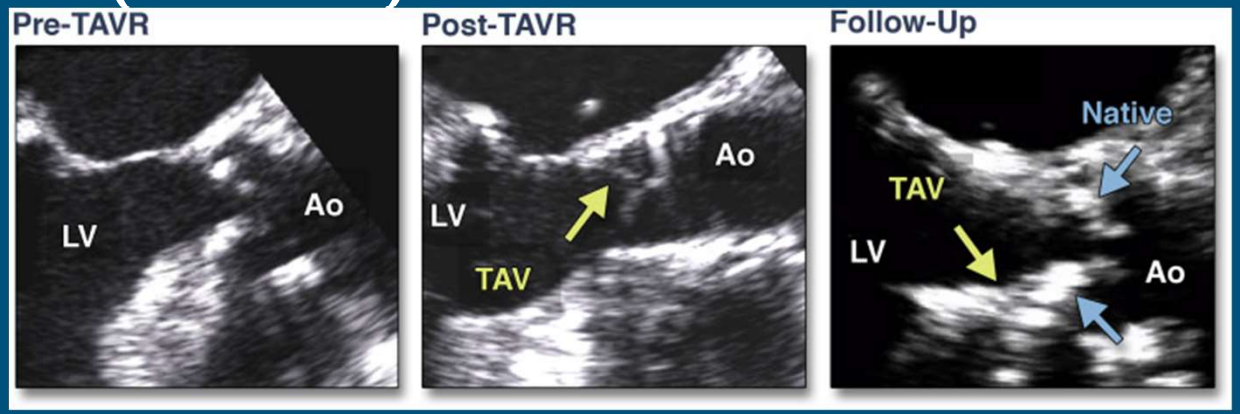

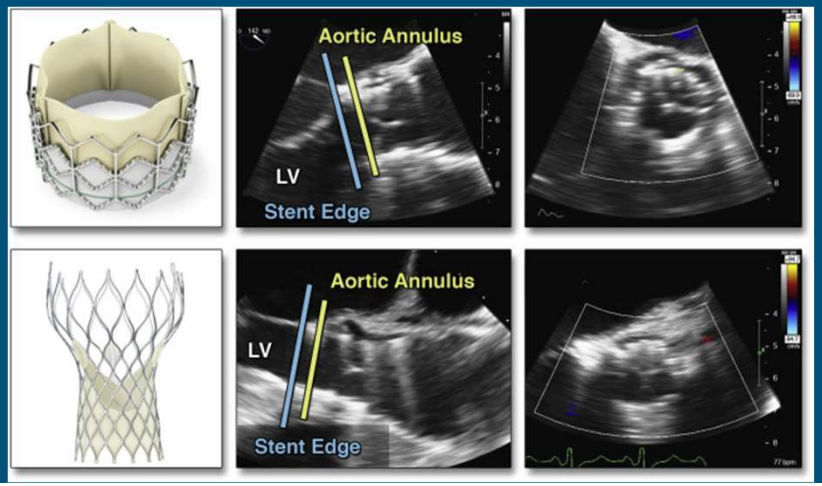

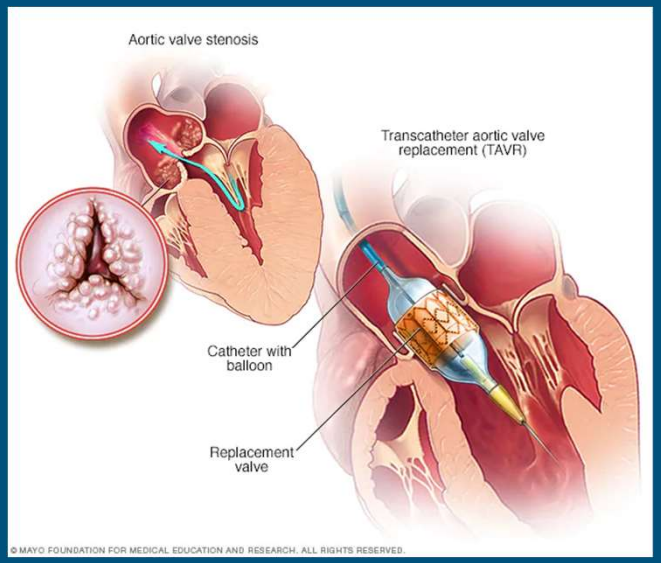

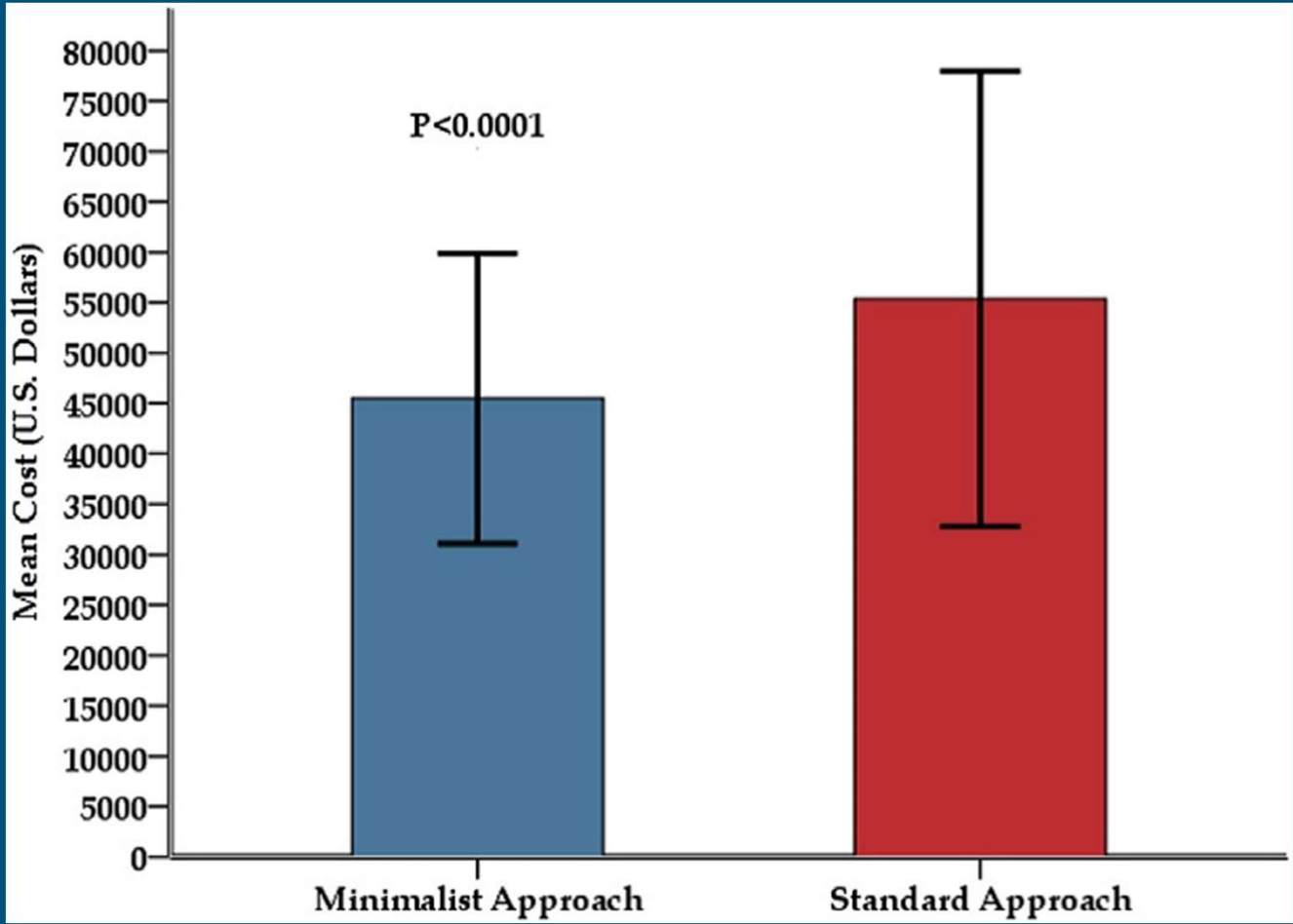

- No significant difference in survival between implant strategies after a year of follow up;
- Minimal access strategy was associated with significant cost reduction

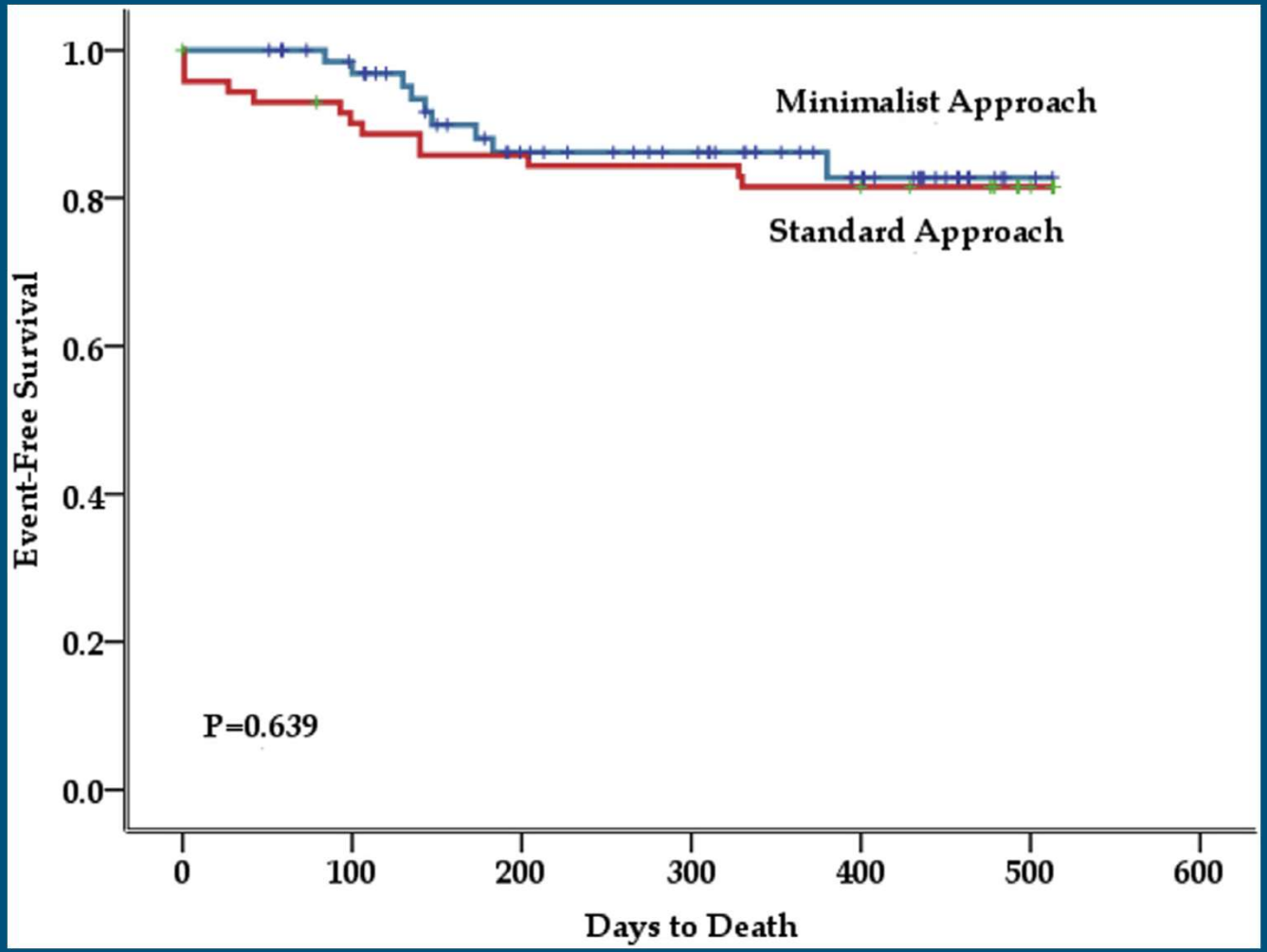

- No significant difference in survival between implant strategies after a year of follow up;

No significant difference in survival/ Paravalvular Regurgitation

TAVR and Prognosis

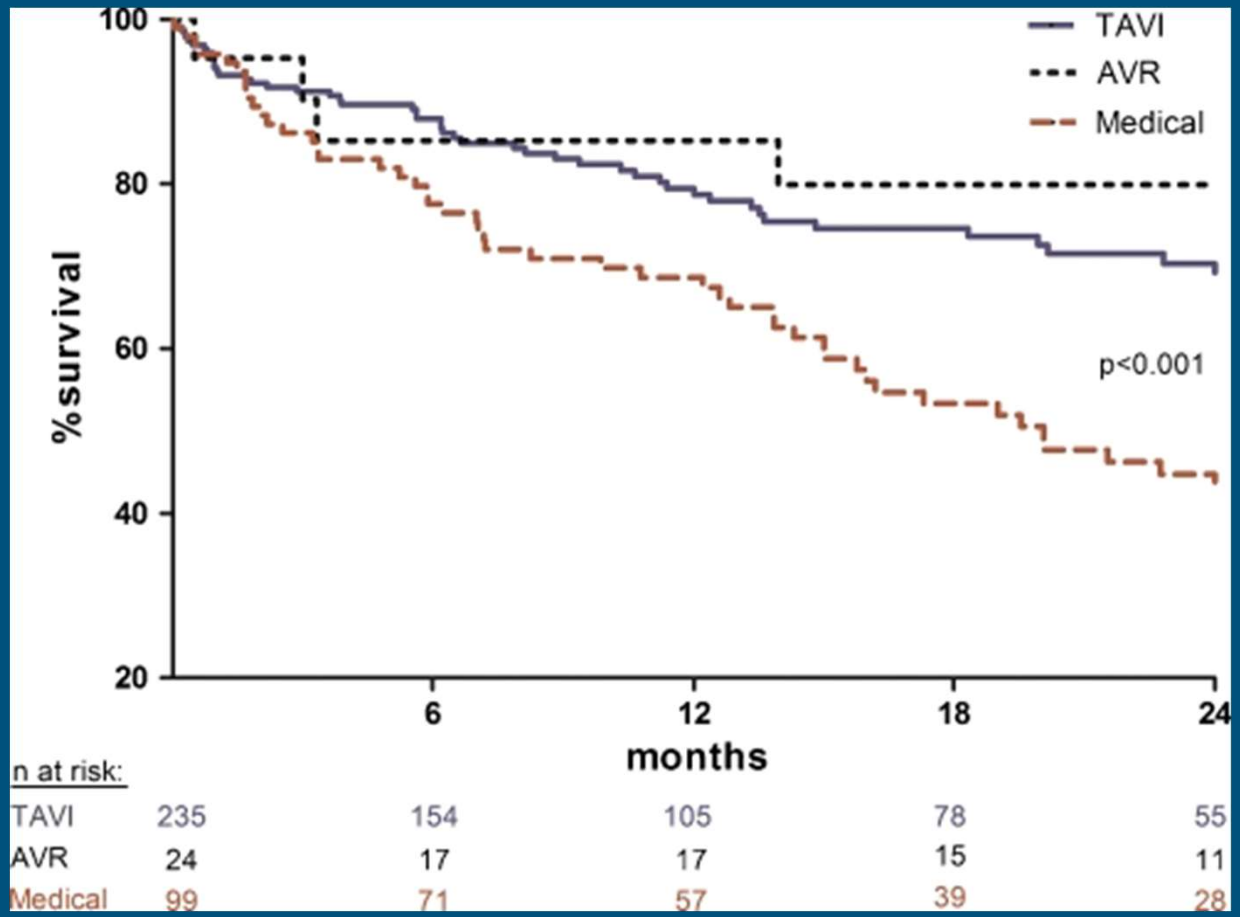

Moves Like Jagger !


Google



Degenerative /Barlow s

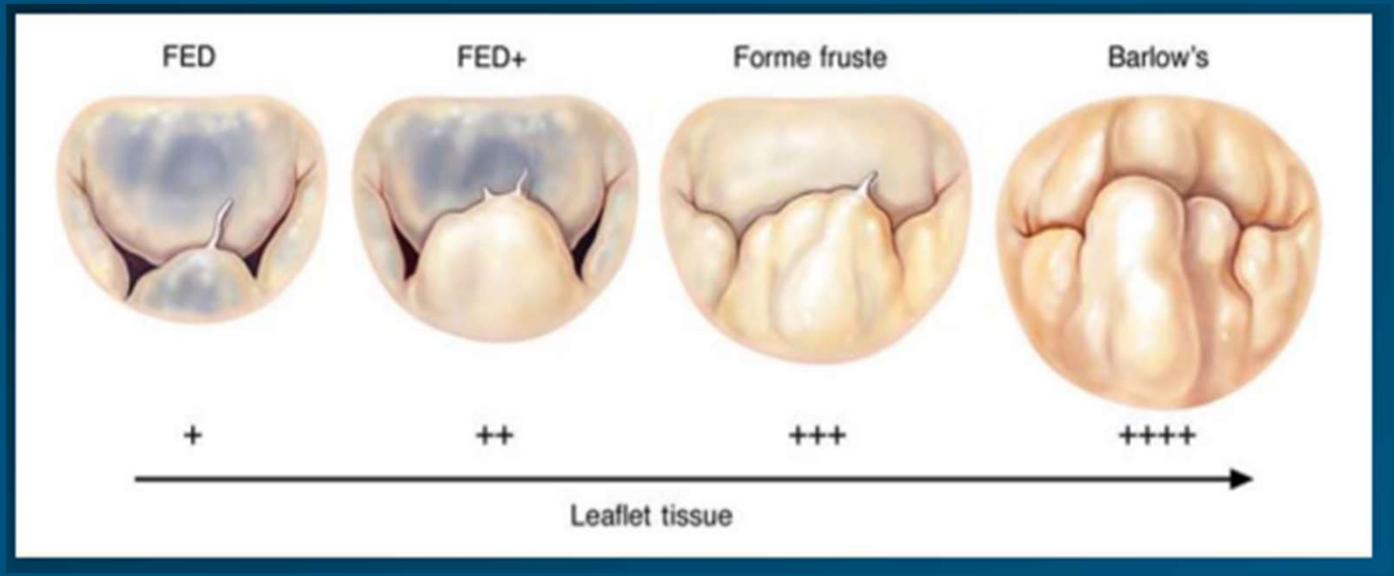

Degenerative MR – Prolapsed / Flail Segment

82-year-old woman
Sudden onset
of exertional dyspnea

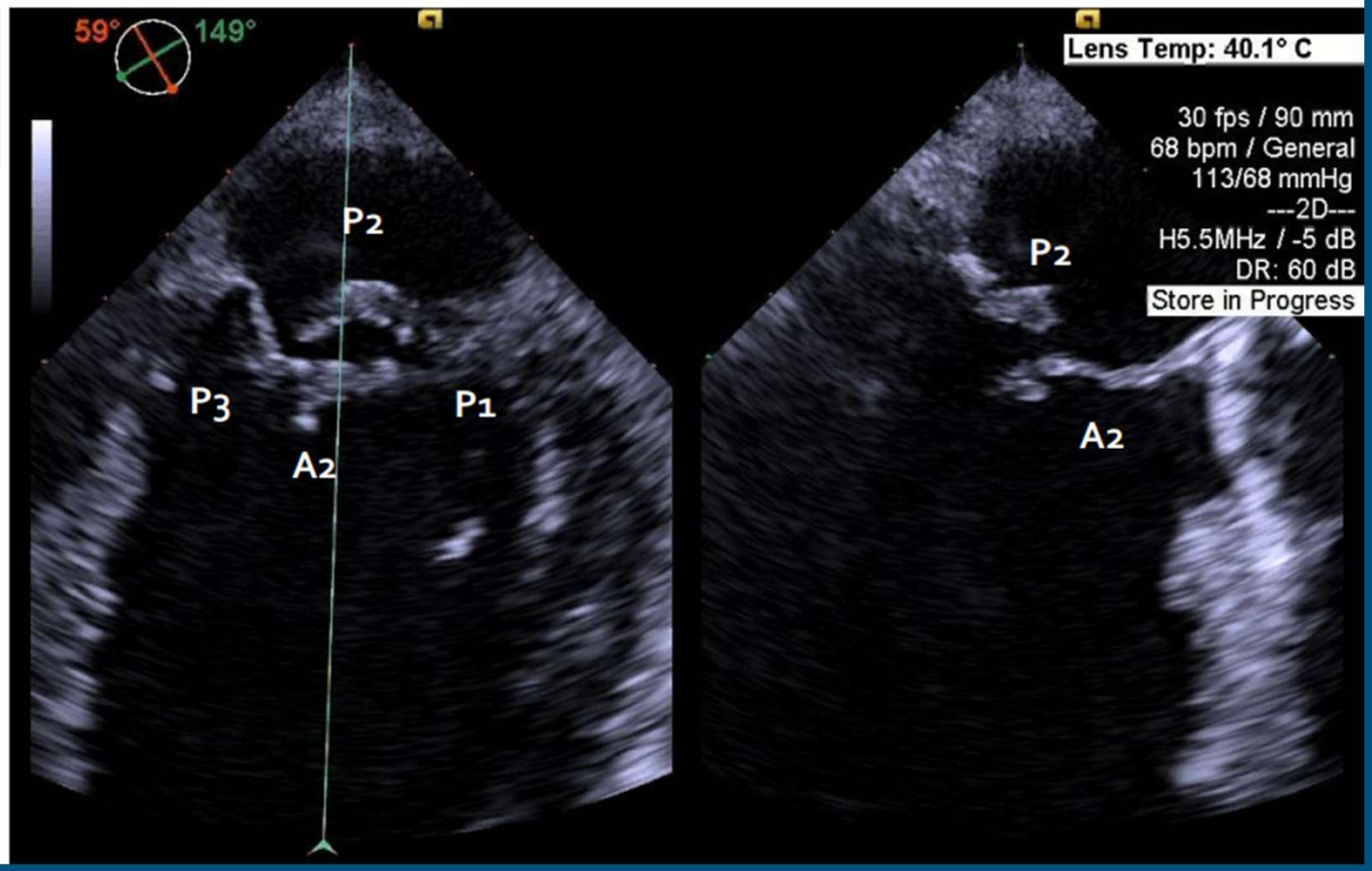

Prolapse

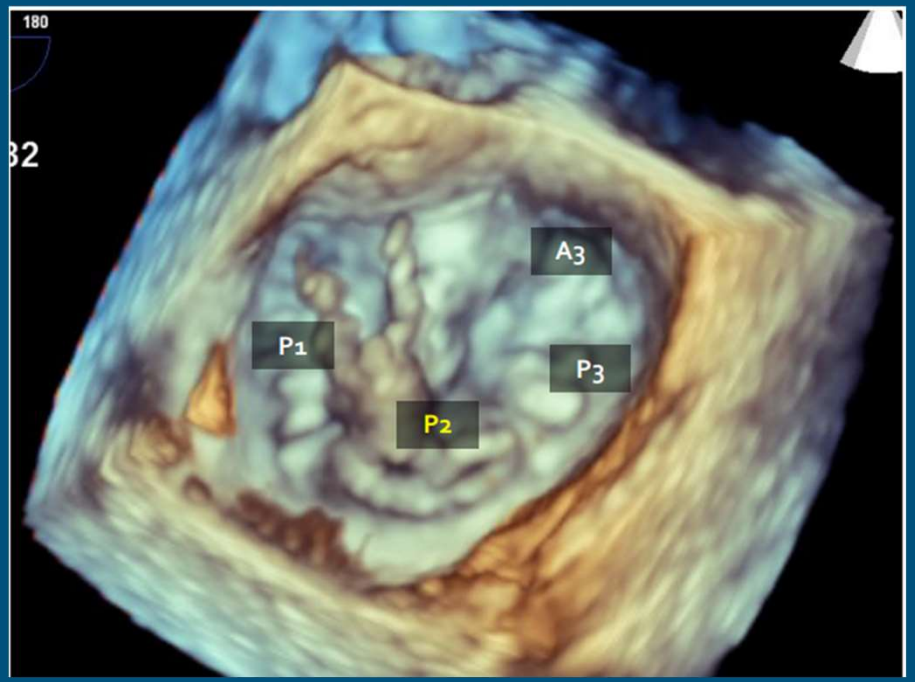

Mitral Interventions

A	B	C	D
MitraClip	Transcatheter Mitral Valve Replacement (TMVR)	Prosthetic Paravalvular Leak (PVL) Closure	Valve-in-Valve
Pascal: MitraClip Alternative			Valve-in-Ring
			Valve-in-MAC

Alfieri Edge-to-Edge Stitch Repair

Ottavio Alfieri

b. 1947

Italian Cardiac Surgeon

First conceived in 1991

Pledgeted Sutures
at the Site of
Mitral Regurgitation
(Typically A2/P2)

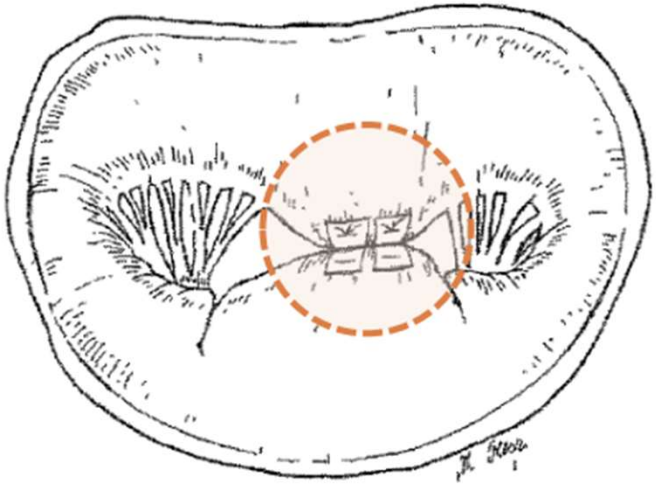

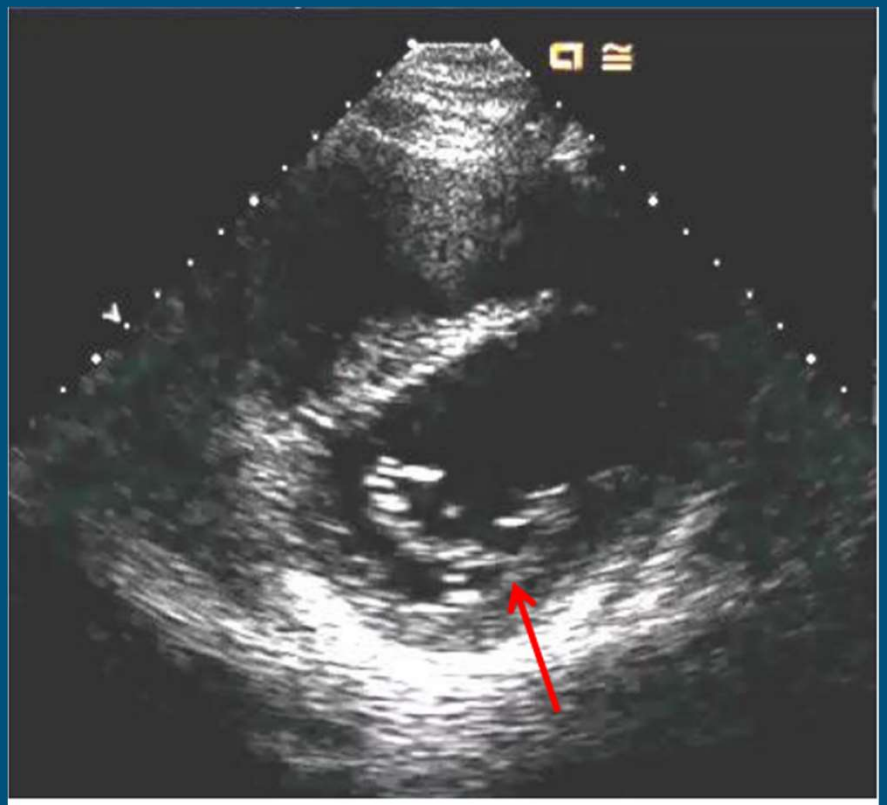

Alfieri Stitch

Mitral Clip

Machine learning in Cardiac Imaging: “profound impact of AI in cardiovascular imaging will have monumental effects on clinical care.

Machine learning in Cardiac Imaging

PROs … are the.. CONs !!

- ML algorithms will connect information from multiple sources in a seamless transition.
- It will automate several tasks which will provide more time for patient interactions for cardiologists.
- It will greatly augment the workflow and ultimately improve medical management.
- AI and ML-driven algorithms are no longer a possibility but an inevitability in the field of cardiovascular imaging."

- Excerpt From: Partho P. Sengupta. "AI in CV Imaging." iBooks.

Thank you.